

The effect of botox for the correction of the gummy smile: A systematic review

Augustė Razmaitė¹, Giedrė Trakinienė²

SUMMARY

Purpose. The aim of the systematic review was to analyze the effectiveness of Botox injections for the treatment of the gummy smile.

Materials and methods. The systematic literature search was done in the databases: PubMed, Embase and Cochrane Library. The articles published from 2013 to 2020 were searched. Only studies on humans were included in this systematic literature review.

Results. During the initial search a total number of 139 articles were detected. However, after the removal of duplications 105 articles were left. Regarding the application of inclusion and exclusion criteria, 6 articles were selected for this systematic literature review.

Conclusions. The results of this study suggested that botulinum toxin was an efficient method to treat the gummy smile.

Keywords: botulinum toxin, gummy smile, excessive gingival exposure treatment, gingival display.

INTRODUCTION

Smile is the most recognized expression of a person which is frequently used in social interaction. It can contribute to person's success or failure, add or subtract self-esteem, assure social skills. Smile is analyzed by eight aspects such as lip line, smile arc, upper lip curvature, lateral negative space, smile symmetry, occlusal frontal plane, dental components as well as gingival components (1).

Gummy smile, on the other hand, being not as aesthetically appealing condition, is defined as excessive, 2 mm or more, exposure of maxillary gingiva upon smiling (2). Several contributing factors are affecting individuals to have a gummy smile. They are either hereditary or inborn and divided into three main categories: cutaneo-mucosal origin, dento-periodontal origin and alveolo-skeletal origin. The first category of gummy smile appears due to inadequate upper lip length, abnormal development of gingiva or muscle hyper function. Dento-periodontal origin gummy smile might develop because of abnormal maxillary incisors' size and clinically short crowns. The final

categories' gummy smile forms due to excessive vertical growth of the maxilla or superioralveolar bone, causing discrepancy between the upper lip and gum line in spontaneous smiling (3). The most common and discussed factor associated with excessive gingival display is altered passive eruption. It is defined as a condition in which the relationship between teeth, alveolar bone in the maxilla and the soft tissues displays an excessive gingiva when gums fail to migrate in the apical direction during the eruption of teeth (4).

Regarding the epidemiology, the prevalence of gummy smile is 10% among the population aged between 20 and 30 years, and is more common among women than men (5). In general, males have a larger muscle volume and require more units of botulinum toxin to achieve the same results as female patients (6). Excessive gingival display decreases with age. Considering gummy smile prevalence among different ethnic groups there were three groups investigated: Germanic Caucasian, Roman Caucasian and Asian. The fact which was found in all ethnic groups is that younger females, aged 35 or less, tend to have higher smile lines than older males, aged 35 or more. More Asian females have excessive gingival display rather than other females while men, especially older ones, mostly have low smile lines (7).

Even though abstention from treatment may be the choice due to lack of motivation, at this state

¹Medical Academy, Lithuanian University of Health Sciences, Kaunas, Lithuania

²Department of Orthodontics, Medical Academy, Lithuanian University of Health Sciences, Kaunas, Lithuania

Address correspondence to Augustė Razmaitė, Medical Academy, Lithuanian University of Health Sciences, A. Mickevičiaus street 9, Kaunas, Lithuania.
E-mail address: auguste.razmaite@gmail.com

some patients may seek treatment. Orthognathic surgeries, orthodontic treatment by incisor intrusion, crown lengthening, gingivoplasty and botulinum toxin injections are all different methods of treating a gummy smile depending on the patient's situation.

The history of botulinum toxin in dentistry begins in 1999 when Howard Katz created the original protocols for the use of Botox in dentistry as a treatment for TMJ disorders resulting from excessive bruxism. Nowadays, botulinum toxin has a variety of utilization and dentistry is not an exception (8). A gummy smile is a condition in which an increasing awareness has been noticed recently. There are different ways to treat it but botulinum toxin injections are one of the most common method. Although procedures may have some side effects, there are a plethora of benefits. The procedure for the Botox injection is as follows: for correction of gummy smile, Botox is injected into the hyperactive elevator muscles of lip blocking excessive contractions and thus preventing the lip from being pulled too far up while smiling.

The aim of this study was to review systematically literature data and discover the effect of Botox for the correction of the gummy smile.

Hypothesis of this systematic review was that the use of Botox for the treatment of a gummy smile was an alternative method to treat this pathology.

MATERIALS AND METHODS

Types of publications

This review included only studies on humans published in English with the exclusion of literature reviews or abstracts.

Types of studies

The recent review included all retrospective and prospective studies published between 2013 and 2020.

Information sources

The publications were collected from PubMed, Embase and Cochrane Library.

Population

Studies of 15-50 year old patients who had Botox injections for the treatment of a gummy smile were selected.

Literature search strategy

An initial search in the electronic libraries was conducted according to PRISMA guidelines by the use of several key words and inclusion-exclusion

criteria. The search was done in three different databases: PubMed, Embase and Cochrane Library. Only articles in English were included. The keywords used for the search were: "botulinum toxin and gummy smile", "excessive gingival exposure treatment", "gingival display". Selection and filtration were done by reading the titles of the articles and their abstracts. If the article corresponded to the criteria of inclusion of review then the entire article was read. Articles that met the following criteria were reviewed and included in this systematic review:

1. Provides information about patients before treatment
2. Uses Botulinum toxin A
3. Injects dose of Botox of 2.5 to 5 units
4. Describes progress of treatment
5. Measures results of procedure

Studies that included patients with deviations, for example pregnant women or allergic people, were excluded.

NBCI, Research gate search resulted in 139 titles that potentially met the inclusion criteria. After reviewing all the abstracts and searching of reference lists of published review articles 34 studies were identified as eligible. After review and data extraction 6 studies met the inclusion criteria and they were included in the final systematic review.

Quality of selected articles was determined by PRISMA checklist. Figure 1 represents the process for article selection with the use of a flow chart.

Assessment of bias risk

The risk of bias was assessed with Newcastle-Ottawa Quality assessment scale modified for the systematic review. All studies showed low risk and high quality (Table 1).

RESULTS

A total of 6 studies were included in this review (Table 2).

Study characteristics

The sample size in the selected studies varied from 1 to 30 with the age range from 15 to 50. The majority of subjects were women because a condition called gummy smile usually occurs for females (Table 3).

Before the injection the gingival exposures of all patients were measured as well as two weeks after the procedure.

Methods of Botox injection

For injections Botulinum toxin A was used. It was recognized that minor variations existed in

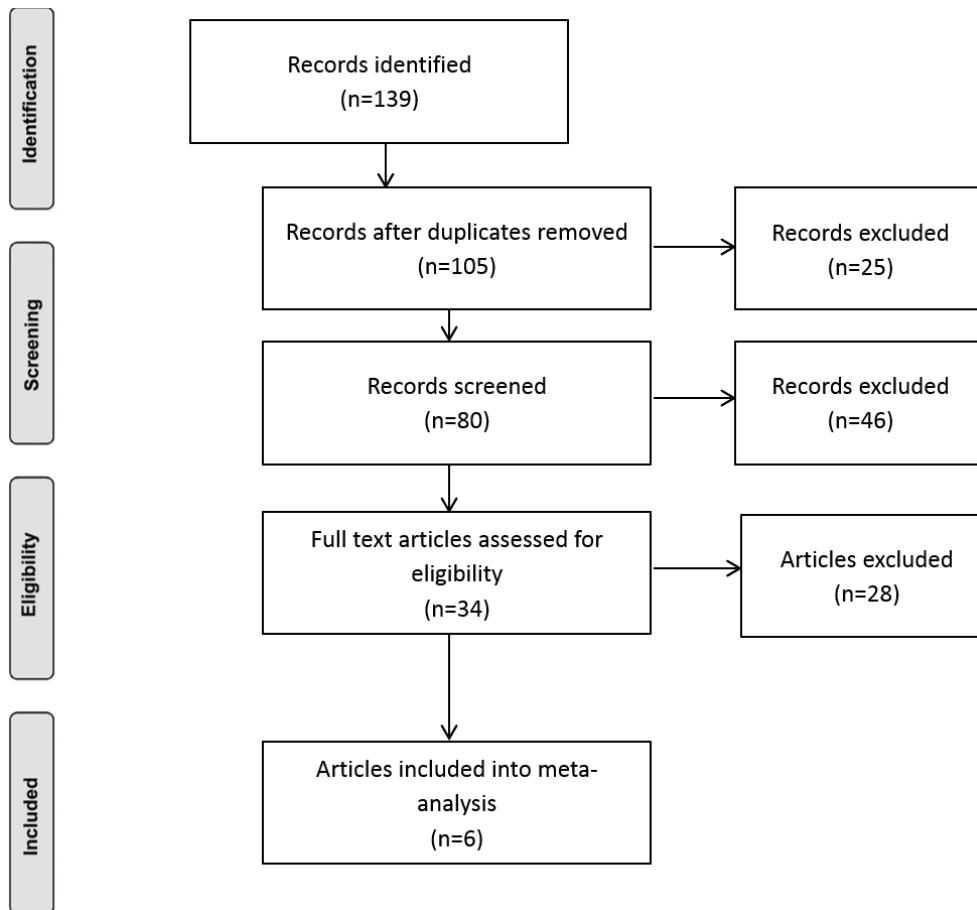


Fig. 1. Flow diagram of studies selection according PRISMA guidelines

quantity of injected Botox which varied from 2.5 U to 5 U. The solutions, which were used for injection, were made by diluting Botox with sodium chloride solution.

Even though the same type of Botox was administered in groups, the methods of injection were different, thus, all the studies included in this review were divided into three groups according to the method of injection. Although the sample sizes differ in groups, ratio between quantity of males and females is similar and the majority of patients are women, therefore, gender does not influence the analysis of results. Age ranges are wide in all three

levator labii superioris and zygomaticus minor muscles triangle, at the level of the nostril opening. The third group (G3) also differs in a way how the Botox was administered. The landmarks for injection were the following: 2 mm lateral to the alar-facial groove at the level of the nostril opening, 2 mm lateral to the first injection in the same horizontal plane and finally 2 mm inferior and between the first two sites. Injection sites were determined by palpation. Hence, all three groups of researches applied different methods of botulinum toxin administration. First of all, the number of needle insertions varied from one to four. Additionally, places of a face where Botox was

groups and does not exceed the age of 50, thus, the impact of age is not relevant in this review. The first group (G1) of patients had 2.5 units of Botulinum toxin A injected into four sites of the face. The needles were inserted in two places on both sides of the face. The points of injection were overlaps of certain muscles: levator labii superioris alaeque nasi and levator labii superioris muscles as well as levator labii superioris and zygomaticus minor muscles on each side of the face. The second group (G2) had a slight different administration of Botox dose. The Botulinum toxin A was injected into one site of the face in the middle of levator labii superioris alaeque nasi,

injected diverge. Therefore, results and duration of the effect differed.

The evaluation of the efficiency of Botox for the correction of a gummy smile was done by the measurements in digital photos, performed before and after injection. Usually, three reference points were used in the studies for

Table 1. Risk of bias assessment according to Newcastle- Ottawa Quality

No.	Study	Selection (of 3 stars)	Comparability (of 2 stars)	Outcome (of 2 stars)	Total (of 7 stars)
1.	Sanju Somaiah MK <i>et al.</i> 2013 (13)	3	1	2	6
2.	Afnan F Al-Fouzan <i>et al.</i> 2017 (9)	3	1	2	6
3.	Dinker S. <i>et al.</i> 2014 (2)	2	1	1	4
4.	Jessica S. Suber <i>et al.</i> 2014 (14)	3	1	1	5
5.	Deniz-Üner D <i>et al.</i> 2017 (11)	3	1	2	6
6.	Táisa Figueiredo Chagas <i>et al.</i> 2018 (15)	3	2	2	7

measurement: RP1 – median point on the lower margin of upper lip; RP2 – midpoint of the gum line of maxillary central incisors; RP3 – point denoting the incisal edge of the maxillary central incisor. The distance between RP1 and RP2 is claimed as gingival display during smile. RP3 was used as a reference point when RP2 became invisible after botulinum toxin injection.

After the procedure patients were instructed to avoid physical activities, lying down or massaging the injection site for at least 4 hours.

Results of the gummy smile changes

The results were evaluated after 2 weeks period of time using the same reference points and position. Until then botulinum toxin's effect improved to its maximum capacity. The amount of improvement equals to the distance between the lower margin of the upper lip to the incisal edge before the injection minus the distance between the lower margin of the upper lip to the incisal edge after the injection (9). The results of the changes of gingival exposure before and after the injection of Botox are shown in the Figure 2.

Improvement of gingival exposure was compared with the picture prior treatment, no control patient was used. Before the treatment, the interval of first group (G1) patients' gingival exposure was 3-5 mm in the incisor region during posed smile. After the Botox administration and two weeks of healing gummy smile reduced to a normal range – approximately 0.95 mm. A duration of the effect lasted for three and more months, depending on the patient, while increase of gingival exposure began at the end of

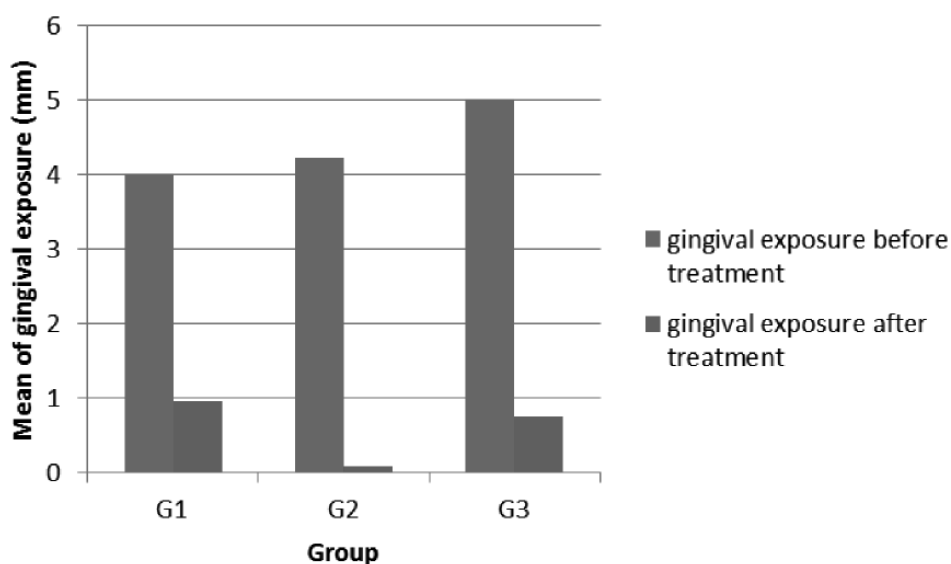


Fig. 2. Changes of gingival exposure before and after the injection of Botox

first month. In comparison, the second group's (G2) data pre-treatment was similar – 4.62 to 5.2 mm of gingival display. The measurements after two weeks were close to 0.09 ± 1.06 mm or as it is claimed the gingival show disappeared. Such results lasted approximately four months, but depending on muscle activity could continue up to six months. Finally, the third group's (G3) average of gingival display before treatment was measured 3-7 mm above the central

Table 2. Descriptions of the qualified studies in the review

Study	Year of publication	Diagnostic evidence	Follow – up	Number of patients treated
Sanju Somaiah MK <i>et al.</i> (13)	2013	Patients reporting, Measuring before and after	90 days	10
Afnan F Al-Fouzan <i>et al.</i> (9)	2017	Patients reporting, Measuring before and after	14 days	23
Dinker S. <i>et al.</i> (2)	2014	Patients reporting, Measuring before and after	14 days	1
Jessica S. Suber <i>et al.</i> (14)	2014	Patients reporting, Measuring before and after	14 days	14
Deniz-Üner D <i>et al.</i> (11)	2017	Patients reporting, Measuring before and after	15 days	8
Taísa Figueiredo Chagas <i>et al.</i> (15)	2018	Patients reporting, Measuring before and after	14 days	30

Table 3. Study sample characteristics

Group number and name	Sample size	Males	Females	Age range
1 G1	11	2	9	18 – 40
2 G2	61	1	60	15 – 50
3 G3	14	1	13	23 – 48
Total	86	4	82	15 – 50

incisors. Post treatment and healing period the gingival exposure drastically decreased to 0.75 mm. Treatment effect was noticeable for three months.

Although the results are not exactly the same, they are similar and differ just slightly. Therefore, it is obvious that despite the different techniques of Botox administration, results are close to being identical. However, the longest duration of procedure's effect is in the second group. It is followed by the rest of the groups. What is more, patients of the second group tended to have the smallest gingival exposure post injection and healing period of two weeks. On the other hand, the most significant improvement was noticed in the third group, while the first group also holds positive improvement. Furthermore, it was noted that patients did not develop any abnormal side effects such as swelling, redness, bruise or infection after procedure. In conclusion, botulinum toxin had a positive impact and temporarily eliminated the undesirable condition – gummy smile.

DISCUSSION

The results of this systemic review indicated that Botulinum toxin A injection is an effective way to treat gummy smile. The aim of the recent review was to evaluate effect of botulinum toxin injections as a non-invasive correction of gummy smile, to compare different treatment techniques and results. Moreover, the article aims to discuss botulinum toxin's abilities in other dental procedures as well as its benefits and drawbacks. These days, the usage of Botox is a non-surgical way to treat excessive gingival exposure and it is advantageous because of its easy and safe application, low risk and reversible effects. What is more, Botox is beneficial for patients psychologically. However, there is a downside of it. Botulinum toxin has a short term effect or may be a reason for asymmetric smile due to improper injection technique.

The other method for treating of the gummy smile is surgical. Compared Botox treatment and orthognathic surgery in order to correct gummy smile there are a lot of differences. First of all, the amount of gingival exposure improvement varies. Treating this condition with botulinum toxin an average reduction of gummy smile is 3 – 4 mm, whereas orthognathic surgery makes an approximately 5 mm improvement. It is obvious that surgical treatment is more effective, even though, it is not always necessary which means that Botox injections may work well enough. In addition, the effect duration of non-surgical botulinum toxin treatment varies from

three to four months depending on muscles activity. In comparison, result of surgical treatment remains approximately 6 months and lip slowly reverts back towards its original position at the end of 12 months (10). It is clear that invasive treatment has longer effect. Furthermore, both procedures might have side effects. Pain, swelling, bleeding, sensitivity of teeth caused by exposed roots, poor healing caused by infections or trauma to the gums post-surgery, leading to gum recession as well as a slight chance of poor esthetic results are a few of surgical treatment side effects (6). Regarding Botox injections' side effects, conditions such as pain, bruising, erythema, edema, tenderness, headache, infection, numbness, vasovagal attack and loss of consciousness may appear. What is more, weakness in facial muscles, asymmetry in limb movements, xerostomia, affected smile and mimic movements, limited mouth opening, double vision, weakness in swallowing, jaw dislocation and voice changes are rare but possible (11). However, most studies acknowledged that side effects are very uncommon which leads to conclusion that botulinum toxin is safe to use. Additionally, Botox injection procedure is simple due to its short duration. In comparison to orthognathic surgery, which usually lasts a few hours, botulinum toxin's doses are injected within a few minutes. Adding more to the account, treatment with Botox is reversible, therefore, it is beneficial comparing to surgery, which must be done flawlessly the first time. The recovery period as well as cost factor are also contributors to deciding which treatment should be applied. Both methods may be applied on the same patient depending on the situation or individually regarding the etiology of gummy smile (12). Botox is recommended for patients whose gummy smiles are mainly caused by hyperactive lip muscles. Taking all benefits and drawbacks into account, the treatment should be based on individual indications, decided by a professional and approved by a patient.

In conclusion, after the botulinum toxin's injection, gingival exposure reduced drastically, therefore, the effectiveness of Botox in dental procedures is undeniable. The difference between methods of injection did not make a significant change in results. Gender and age range did not influence the results. Even though the results are temporary, Botox is extensively used for aesthetical reasons in dentistry.

CONCLUSIONS

Botulinum toxin is very effective and quick in the reduction of excessive gingival exposure because

up to 5 mm decrease in gummy smile was observed after injections. The best results were noted 2 weeks post administration. The effect of Botox lasted approximately three months and more. Generally, the Botox treatment is safe when its technique and quantity are administered properly. To sum up, regarding

the review results, botulinum toxin injections are effective for treating gummy smile.

CONFLICT OF INTEREST

The authors do not have conflicts of interest.

REFERENCES

1. Sabri R. The eight components of a balanced smile. *J Clin Orthod* 2005;39:155-67 (RG)
2. Dinker S, Anitha A, Sorake A, Kumar K. Management of gummy smile with Botulinum Toxin Type-A: A case report. *J Int Oral Health* 2014;6(1):111-5
3. Izraelwicz-Djebali E, Chabre C. Gummy smile: orthodontic or surgical treatment? *Dentofacial Anom Orthod* 2015;18:102. Published online: 04 September 2015.
4. Basel Mahardawi, Teeranut Chaisamut, Natthamet Wong-sirichat Gummy Smile: A Review of Etiology, Manifestations, and Treatment. *Siriraj Medical Journal* 2019; 71(2): 168-174
5. Moura D., Lima E., Lins R., Souza R., Martins A., Gurgel B. The treatment of gummy smile: integrative review of literature. *Clin. Periodontia Implantol. Rehabil. Oral Vol.* 10(1); 26-28, 2017.
6. Diana Mostafa A successful management of sever gummy smile using gingivectomy and botulinum toxin injection: A case report. *International Journal of Surgery Case Reports Volume 42*, 2018, Pages 169-174.
7. Jorgen Jensen, Andreas Joss, Niklaus P. Lang The smile line of different ethnic groups in relation to age and gender. *Acta Med Dent Helv* 4: 38-46 (1999)
8. Kyung-Soo Park, Chi-Heun Lee, Jung-Woo Lee Use of a botulinum toxin A in dentistry and oral and maxillofacial surgery. *J Dent Anesth Pain Med.* 2016 Sep;16(3):151-157.
9. Al-Fouzani AF, Mokeem LS, Al-Saqat RT, Alfalah MA, Alharbi MA, Al-Samary AE. Botulinum Toxin for the Treatment of Gummy Smile. *J Contemp Dent Pract* 2017;18(6):474-478
10. Mudnoor Manjunath Dayakar, Sachin Gupta, Hiranya Shivananda Lip repositioning: An alternative cosmetic treatment for gummy smile. *J Indian Soc Periodontol.* 2014 Jul-Aug; 18(4): 520-523.
11. Deniz-Üner D, Serhat-Å,,Å°zol B The Correlation between the Upper Lip-Drop and the Amount of Gingival Display in the Correction of the Gummy Smiles with Botulinum Toxin. *Int J Drug Dev & Res.* 2017; 9:18-21
12. Irineu Gregnanin Pedron, Alessandro Mangano Gummy Smile Correction Using Botulinum Toxin With Respective Gingival Surgery. 2018 Sep; 19(3): 248-252.
13. Sanju Somaiah M. K., Sunil Muddaiah, Balakrishna Shetty, Vijayananda K. M., Muraleedhara Bhat, Shetty Priyesh Shankar Effectiveness of botulinum toxin A, in unraveling gummy smile: A prospective clinical study. *APOS Trends in Orthodontics* 2013;3(2):54
14. Jessica S. Suber, Trish P. Dinh, Melanie D. Prince, Paul D. Smith OnabotulinumtoxinA for the Treatment of a "Gummy Smile". *Aesthet Surg J*; 2014 Mar; 34(3):432-7
15. Chagas TF, Almeida NV, Lisboa CO, Ferreira DMTP, Mattos CT, Mucha JN. Duration of effectiveness of Botulinum toxin type A in excessive gingival display: a systematic review and meta-analysis. *Braz Oral Res.* 2018;32:e30. doi: 10.1590/1807-3107bor-2018.vol32.0030.

Received: 07 10 2020

Accepted for publishing: 24 09 2021