

Various wound closure ways after impacted lower wisdom teeth removal: A review

Žygimantas Petronis*, Jonas Zigmantavičius*, Albinas Gervickas*

SUMMARY

Objective. Evaluate the influence of different wound closure methods in terms of pain, swelling, trismus, infection and healing time after third molar extraction.

Material and methods. A literature analysis was performed according to PRISMA guidelines in search of clinical trials published between 2015 and 2020. Databases were searched using different combinations of the following keywords: mandibular impacted OR retained wisdom teeth OR third molar removal OR extraction AND surgical removal AND discomfort OR pain OR trismus OR swelling AND drain OR drainage. The literature search resulted in a total of 364 publications. Finally, 12 study articles were used in the present review, following a selection based on the preestablished eligibility criteria.

Results. The significant difference between various wound closure ways and postoperative pain, swelling and trismus has been found in 8 of 12 analyzed articles. Three of five established beneficial effect of drain application. In other articles, examining different wound closure methodologies, significant benefits were found by using buccally based triangular, buccal mucosal-advancement, and modified envelope flap. Suture-less anterior releasing incision and secondary wound closure also could be favorable after removing impacted third molars.

Conclusion. There was no significant effect of a rubber drain on swelling, pain, trismus, or wound infections after removal of the asymptomatic impacted third molar(s). Secondary wound closure was found to ensure lower pain, swelling and trismus ratio with comparison to primary wound closure.

Key words: third molar removal, wound closure, drain, suture, flap technique.

INTRODUCTION

Impacted wisdom teeth are third molars that are not expected to erupt into a functional position. Wisdom teeth become partially or completely impacted owing to lack of space, obstruction, or abnormal position. The mandibular third molars, or wisdom teeth are common in 90% of the population (1). It is estimated that the retention of wisdom teeth in mandibular is from 1.64 to 2.3 times higher than in maxillary (2, 3). The frequency of mandibular wisdom teeth impaction is common in 79.6% of the population (4). Impaction can be present in different patterns and levels. For position evaluation of mandibular third molars, several classifications have been proposed (5).

The Winter and the Pell and Gregory classifications are usually used for predicting the difficulty of the surgical procedures:

- The Winter classification is based on the inclination of the impacted wisdom tooth to the long axis of the 2nd molar.
- Pell and Gregory's classification is based on the relationship between the impacted lower wisdom tooth to the ramus of the mandible and the 2nd molar.

The most commonly observed position according to Winter classification is mesioangular type (41.8%) and relative to the Pell and Gregory classification, IIB (26.4%) is the most prevalent type (5).

Impact or eruption in an incorrect position can lead to clinical diseases including pericoronitis, dental caries, root resorption of the adjacent teeth, the development of cysts or tumors (6-8). Therefore, removal is often required to avoid these morbidities. Although the surgical removal of mandibular wisdom

*Department of Maxillofacial, Faculty of Dentistry, Lithuanian University of Health Sciences, Kaunas, Lithuania

Address correspondence to Žygimantas Petronis, Department of Maxillofacial, Faculty of Dentistry, Lithuanian University of Health Sciences, Eivenių g. 2, LT-50161 Kaunas Lithuania. E-mail address: petronis.zygimantas@gmail.com

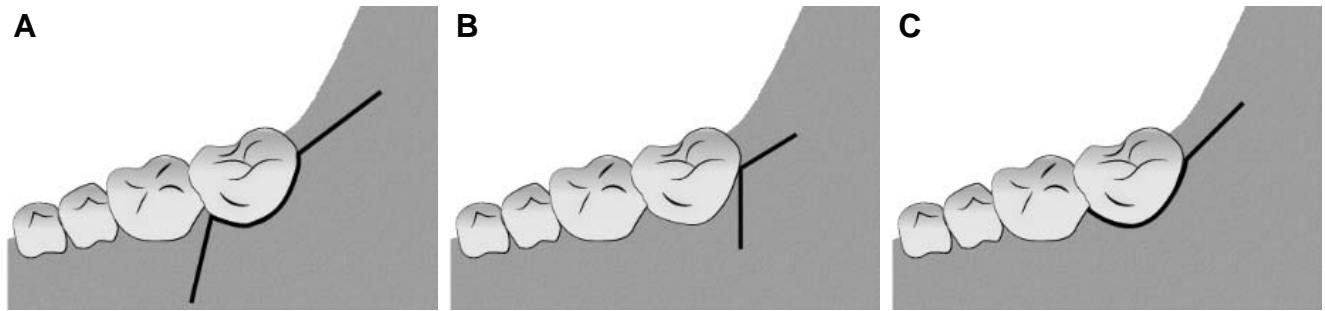


Fig. 1. Terence Ward's (three-cornered) (A), triangular (B) and envelope flaps (C)

teeth is a commonly performed operation undertaken in oral and maxillofacial surgery, occurrence of complications remains a serious problem post extraction. Alveolar or lingual nerve damage, temporomandibular joint disorders and infections are the most severe complications, however the prevalence of these complications is low and reaches up to 9.5% (9–11). Pain, trismus, dry socket and swelling are the most common complaints on postoperative days and cause daily routine difficulties to the patients (12, 13).

Despite the use of various drug combinations including non-steroidal anti-inflammatory drugs (NSAIDs), corticosteroids and antibiotics, the alleviation of postoperative discomfort for the patient is still challenging in the oral surgery field (14, 15). During recent years, therapeutic methods such as primary or secondary wound closure and insertion of various types of drains (tubes, rubber drains) were investigated to establish the potential differences in the efficacy of alternative surgical techniques in reducing postoperative discomfort and improving the condition of patients. Secondary wound closure and drains are based on the principle that these measures permit the drainage of the inflammatory exudate located in the tissue spaces and lead to minimal postoperative tension of the surrounding soft tissues. However, the initial closure of the wound ensures no communication with the oral cavity and thus reduces the risk of postoperative complications. This review is designed to observe the effectiveness of different wound closure and drainage methods used in clinical practice after the removal of impacted mandibular third molars.

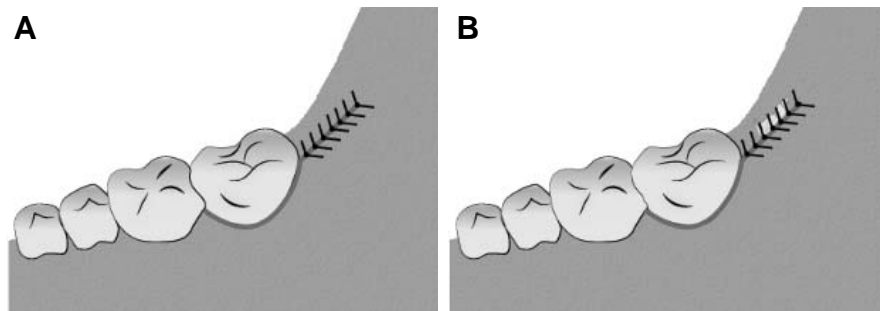


Fig. 2. Completely closed wound (A) and inserted rubber drain (B)

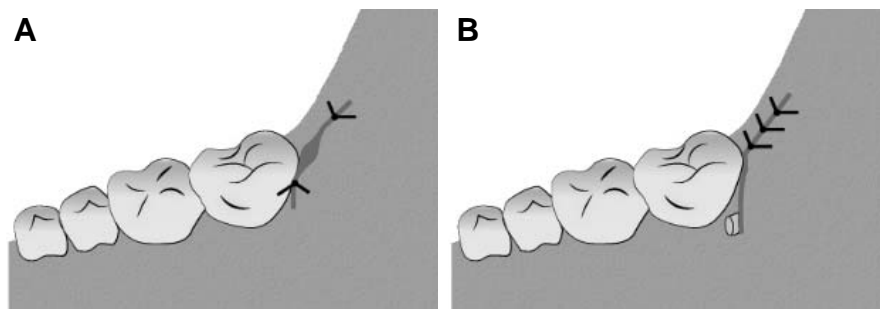


Fig. 3. Partially sutured wound (A) and inserted drain tube (B)

MATERIALS AND METHODS

A literature analysis was performed according to PRISMA guidelines in search of clinical trials published between 2015 and 2020. Electronic and manual literature searches were conducted independently by all authors in several databases, including MEDLINE, Springer Link, Science Direct and Google Scholar. Databases were searched using different combinations of the following keywords: mandibular impacted OR retained wisdom teeth OR third molar removal OR

Table 1. Characteristics of materials based on “SolidWorks®” database of material specifications and scientific data (12, 13)

Patients inclusion criteria	Patients exclusion criteria
<ul style="list-style-type: none"> • Systemically healthy adult patients (18 years and above). • Patients in good medical condition, without local inflammation. • Bilaterally impacted mandibular third molars indicated for surgical removal. 	<ul style="list-style-type: none"> • Patients with systemic diseases. • Allergy or contraindications to the drugs or anaesthetics. • Pregnancy or lactation. Noticeable local inflammation or pathology in the oral cavity.

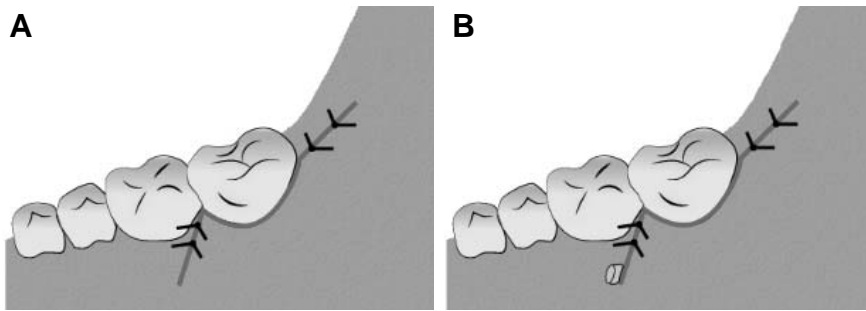


Fig. 4. Primary wound closure (A) and drain tube application (B)

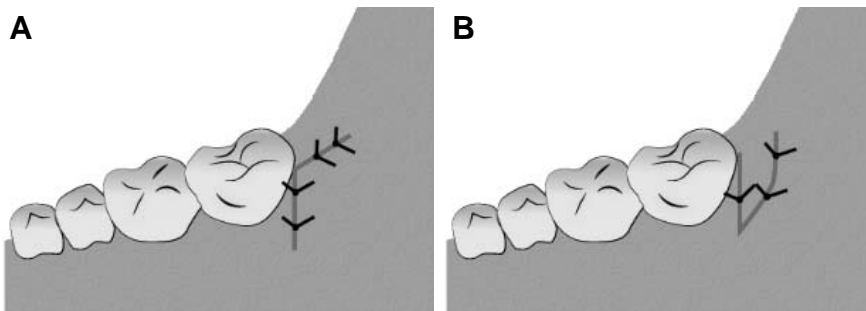


Fig. 5. Buccally based triangular flap (a) and lingually based triangular flap (B)

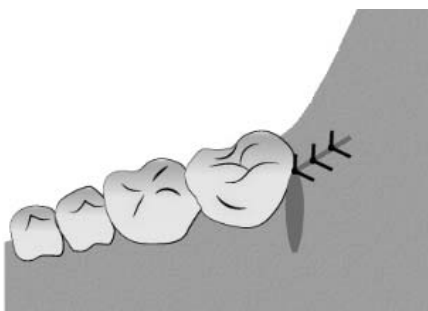


Fig. 6. Sutureless anterior releasing incision

extraction AND surgical removal AND discomfort OR pain OR trismus OR swelling AND drain OR drainage.

The titles and abstracts

were first analyzed, and followed by the selection of complete articles for careful reviewing and analysis according to the eligibility criteria.

The selected studies had to meet the criteria of:

- published in English;
- no older than 5 years;
- clinical trials;
- involving only humans.

All case reports or case series, animal, in vitro studies were excluded from the study. The literature search resulted in a total of 364 publications. Data were collected on author, year of publication, study design, study methods/measures and results. Results were checked for duplicates, the inclusion/exclusion criteria applied, the titles, abstracts and full texts were reviewed in order to exclude all inadequate articles. After that, patients inclusion and exclusion criteria were applied (Table 1). Finally, 12 study articles were used in the present review, following a selection based on the preestablished eligibility criteria.

Measurement methods in selected articles

Patients rated their current pain on visual/verbal analog scale (VAS). The mouth opening was determined by measuring the maximum interincisal distance. For facial swelling evaluation, different methods were used: 3D optical scanner (16), facial photographs (17), line measurement between reference points (18, 20, 21, 23-25), tape measure (19, 22, 26), visual measurement (27).

Surgical procedures in selected articles

Surgical procedures were carried out under local anesthesia. For the inferior alveolar block, 2% lignocaine hydrochloride (1:80000/ 1:100000/ 1:200.000 epinephrine)

(17-20, 23, 26, 27) or 4% articaine (1:100.000 epinephrine) (21, 22, 25) were used in procedures. Two articles (16, 24) did not describe the local anesthetic used. Usually, Terence Ward's (three-cornered) (Fig. 1 A) (18-20, 25, 26), triangular (Fig. 1 B) (17, 21-23), envelope (Fig. 1 C) (16) or modifications of these flaps (21, 22, 27) were used. One study (24) did not specify the technique used. Mucoperiosteal flap reflected and bone covering the crown of the impacted tooth was adequately removed under constant irrigation. Teeth were separated by means of a straight bur, if necessary, tooth follicle or granulation tissue was then additionally removed. Further procedures were performed according to different methodologies.

Postoperative instructions

The patients were advised to cool the side on which the surgery was performed, maintain adequate oral hygiene, follow a cold and soft diet for a period of 24 hours after the surgical procedure, avoid smoking, limit activity at least for the rest of the day (6, 16, 17, 20, 21). Medications prescribed postoperatively (16-20, 22-26): analgesic (400mg/600 mg ibuprofen every 6-8 h for 3 days / 50mg diclofenac three times a day for the next 3-5 days / Flurbiprofen 100mg two times per day (22), paracetamol 500 mg 3 times per day for 3 days), antibiotics (cephalosporin and metronidazole (17) for 3-5 days, amoxicillin 500 mg/750 mg/1000mg two or three times per day for 3-5 days or clindamycin 600 mg/day (19) for 4 days). In two studies antibiotics were not prescribed (16, 21) and one clinical trial did not specify medication use (27).

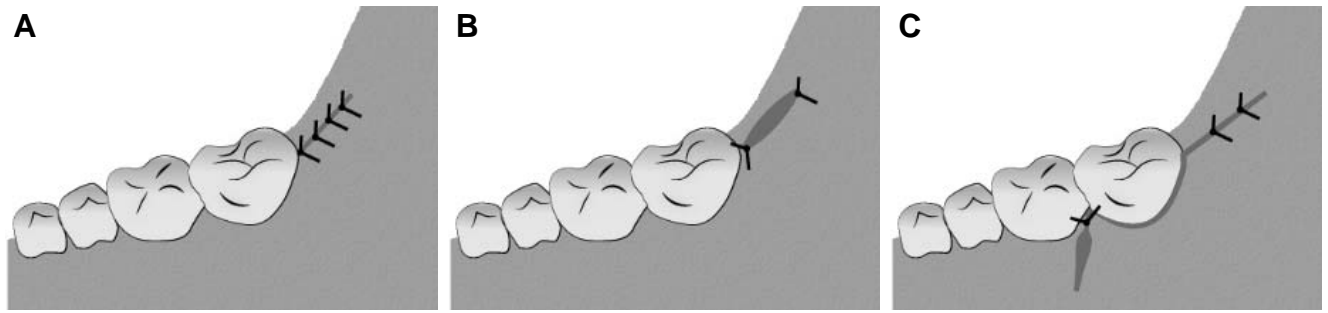


Fig. 7. Primary (A), secondary occlusal [24] (B), and secondary buccal [25] (C) wound closures

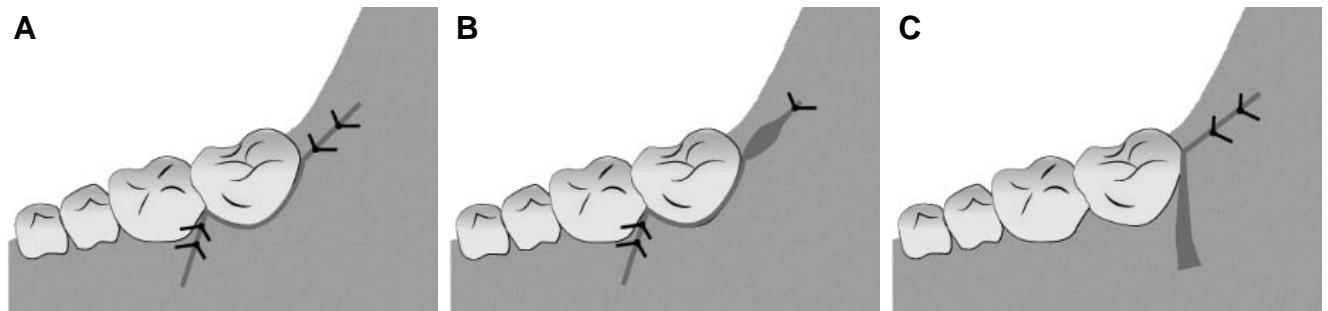


Fig. 8. Primary (A), secondary (B) wound closures and buccal mucosal-advancement flap (C)

RESULTS

Drains

Insertion of tube drains, rubber drains, strip drains after removal of third molar were reviewed. In a split-mouth-studies by M. S. Katz *et al.* (16) and Ting Hu *et al.* (17), the effect of rubber drain, partially sutured and conventional wound closure on postoperative facial swelling, pain and mouth opening after surgical removal of impacted mandibular third molar were observed. In total, the study included 116 patients with symmetrically impacted wisdom teeth on both sides of the mandibular. The study evaluated postoperative discomfort values on days 3, 7 and 10 postoperatively. Each patient underwent two dental surgery operations, which included a 28-30 days difference. In a study by M. S. Katz *et al.* (16), a rubber drain was introduced into the occlusal surface on one side and the wound was completely closed in a conventional way on the other side (Fig. 2 A, B). In the study of Ting Hu *et al.* (17), a drainage tube was fixed in the area of the vertical incision for the closure of the wound after tooth extraction, and a partially sutured occlusal drainage method was applied on the other side (Fig. 3 A, B).

The results of a study by M.S. Katz *et al.* (16) showed that there was no statistically significant difference between the rubber drain and completely sealed groups in the analysis of swelling and mouth opening on the 3rd and 10th postoperative days. Pain

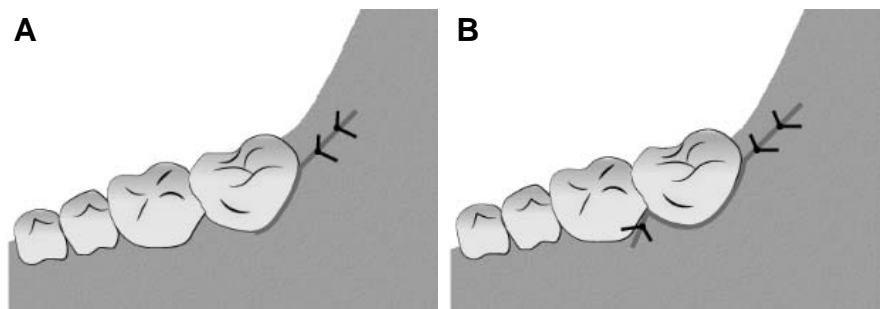


Fig. 9. Modified envelope (A) and modified triangular flap (B)

on the 3rd postoperative day was slightly greater in the rubber drain group but the difference was not significant. The authors state that they did not find a significant positive effect of using a rubber drain after asymptomatic lower wisdom teeth surgical removal; this method could be useful in the presence of preoperative infection.

Analyzing the results of Ting Hu *et al.* (17), it was found that the swelling in the buccal drainage and occlusal drainage groups at 1st, 3rd, 7th day postoperatively was similar and no significant statistical difference was observed. The buccal drainage group demonstrated better hemostasis than did the other group due to the firm occlusal suture. Regarding wound healing analysis, the distal parts of the second molar on the occlusal drainage side showed wedged gaps after 1 month postoperatively and just a few of them healed completely. Meanwhile, in the buccal drainage group, all wounds healed successfully after 1 month. Therefore, the buccal drain pathway method helps to avoid dry sockets, the long-standing wedged

gap in the disto-occlusal site of the second molar and reduces postoperative bleeding.

In some randomized studies (18-20), the effect of tube drains and hermetic wound closure after extraction of impacted wisdom teeth in terms of pain, trismus, swelling was evaluated. 25 to 60 patients with bilateral impacted mandibular third molars participated in these studies. Primary wound closure was used in the no drain tube group. In the experimental groups, a tube drain was inserted in the buccal incision line between the first and second molar (Fig. 4 A, B). The drain was removed on day 2 or 3 postoperatively. Two analyzed articles (18, 20) indicate that less postoperative pain is experienced on days 1, 3, 7 using tube drains compared to the initial wound closure; however, the difference is not statistically significant and only one study by B. O. Koyuncu *et al.* (19) shows a statistically significant reduction in postoperative pain in the tube drain group ($P=0.001$). Using the tube drain, facial swelling data analysis demonstrated significantly better results on days 2 and 3 compared to the group without tube drain ($P\leq 0.05$) (18-20). However, on day 7 swelling results did not differ between groups (19, 20). The results of the trismus evaluation data varied. A study by B. Kumar *et al.* (18) states that maximum interincisal opening in the tube drain group at postoperative day 1 was lower as compared to the group without tube drain, and bigger at postoperative day 3 and 7 but the differences between both the groups were not statistically significant. B. O. Koyuncu *et al.* (19) revealed that mouth opening when the tube drain was used showed significantly better results on days 2 and 7 compared to the group without tube drain ($P\leq 0.017$). A study by Vishal *et al.* (20) indicates that mouth opening was significantly greater on days 1, 3 and 7 in the tube drain group compared to the primary closure group ($P<0.001$). Thus, it can be argued that use of a tube drain could be a useful clinical approach that slightly improves results on pain, trismus and greatly reduces facial swelling after impacted third molar removal procedures.

Sutures / mucoperiosteal flap designs

The present review assesses the most appropriate linguallly and buccally based triangular flap, modified envelope and triangular flap as well as buccal mucosal-advancement flap designs.

In this review, two articles analysed linguallly and buccally based triangular flap (Fig. 5 A, B) (21, 22). The discussed studies included 52 patients with bilateral impacted mandibular third molars in total. For each patient, the impacted molars were removed in two sessions with an interval of 4 weeks between them. According to U. Yolcu and A.H.Acar (21), buccally

based triangular flap group exhibited a significantly lower pain at 12h post-surgery ($P<0.05$) and at each of the first 7 days post-surgery, although this was not statistically significant. Buccally based triangular flap also showed not significantly higher mouth opening values from day 2 to day 21 postoperatively. Facial swelling results did not vary significantly between two groups. In addition, more common occurrence of dehiscence and alveolar osteitis cases at the buccally based triangular flap sites were observed on day 7-21 postoperatively. D. Menziletoglu *et al.* (22) revealed that pain was significantly lower in buccally based triangular flap group for postoperative 7 days ($P<0.05$). It is estimated that mouth opening was statistically higher and facial swelling were significantly statistically lower in buccally based triangular flap group regarding 2nd and 7th postoperative days ($P<0.05$). In this study, much higher frequency of dehiscence was observed two weeks after surgery in the buccally based triangular flap group. The linguallly based triangular flap technique provided more pain, swelling and trismus compared to the buccally based triangular flap technique. However, the risk of dehiscence appears to be less common using linguallly based triangular flap technique.

S.S. Nayak *et al.* (23) investigated the impact of the suture-less anterior releasing incision in a triangular flap design on postoperative healing and announced interesting results (Fig. 6). In this study conducted on 112 patients, it was observed that nonclosure of the anterior vertical releasing incision facilitates drainage of the exudate and significantly decreases postoperative edema and swelling on the first postoperative week compared to the group where anterior and posterior incisions were sutured after removal of the impacted mandibular third molar ($P<0.001$). Comparing the results of these two groups, there was no significant difference in the severity of experienced pain and trismus on postoperative days 1, 2 and 7. However, the authors indicate increased periodontal pocket formation adjacent to the second molar 2 months after surgical removal in the suture-less group.

In the modern clinical practice of these days, the efficiency of hermetical and partial closure of the wound on postoperative pain, trismus and swelling are widely discussed methods. Two clinical trials (24, 25) evaluated primary, secondary occlusal and buccal wound closure methods (Fig. 7 A, B, C). The studies conducted by P. K. Pachipulusu *et al.* (24) and C. Gay-Escoda *et al.* (25), observed higher pain, swelling and lower mouth opening variables in the hermetical wound closure group during the first postoperative week. In a clinical trial by P. K. Pachipulusu and S. Manjula (24), results of pain and swelling were

specified as highly significant ($P < 0.001$). However, C. Gay-Escoda *et al.* (25) did not find significant differences in postoperative values. It is argued that secondary wound closure is thought to be a favorable condition for infection because of an open infection gate. P. K. Pachipulusu and S. Manjula (24) reported only one alveolar osteitis case in the partial wound closure group. The results obtained indicate that partial closure could be more appropriate than primary closure in terms of postoperative pain, swelling, and trismus. Unfortunately, chances of food impaction and infection are higher concerning secondary closure.

Another study investigated the modern flap design which could incorporate the advantages of both hermetically sealed and partial closure while minimizing the disadvantages of both. R. Balamurugan and T. Zachariah (26) conducted a study in which they compared primary and secondary wound closure (Fig. 8 A, B). The study also investigated beneficial effect of a buccal mucosal-advancement flap technique (Fig. 8 C) on the postoperative sequelae post mandibular impacted third molar surgery. The clinical study consisted of 150 patients divided into 3 groups. Primary and secondary wound closures were accomplished in a conventional way by hermetically sealing primary suture and leaving occlusal drainage pathway in the secondary suture. In the buccal mucosal-advancement flap closure technique, mucosa was released from the periosteum and then mobilized as well as undermined by blunt dissection over the buccinator. The buccal mucosal-advancement flap advanced over the socket and sutured without tension, however anterior vertical release was left suture-less. The results showed that buccal mucosal-advancement flap technique overall demonstrated significantly lower pain and higher interincisal opening compared to secondary and primary wound closure on postoperative 2nd, 4th and 7th days ($P < 0.05$). The facial swelling difference between the buccal mucosal-advancement flap group and the secondary wound closure group was also found to be beneficial. It is important to note that no complications of flap dehiscence were observed in the buccal mucosal-advancement flap group. Wound dehiscence was observed in 18 patients' and alveolar osteitis appeared in 4 patients' results regarding the primary wound closure group. Food accumulation and slower healing were seen in 6 patients' results regarding the secondary wound closure.

Another study evaluated a novel modified envelope flap to optimize clinical outcomes and quality of life for patients following mandibular third molar extraction surgery. Q. Xie *et al.* (27) investigated 40 patients with bilaterally impacted mandibular third molars. Each patient underwent dental extraction un-

der incision with modified envelope flap on one side and modified triangular flap on the other side after 4 weeks (Fig. 9 A, B). This study collected data of postoperative pain, trismus and swelling concerning the first 7 postoperative days. Results indicated no significant differences in pain values; however, the swelling degree in the modified envelope flap group was much lower than in the modified triangle flap group; significant difference was seen on days 3 and 7 ($P \leq 0.05$). Modified envelope flap group also reached much better interincisal distance on the 3rd and 7th day ($P \leq 0.05$). To conclude, with regard to the reduced postoperative discomfort rate, modified envelope flap design can be a useful method for removing impacted mandibular third molars.

All reviewed articles are shown in Table 2.

DISCUSSION

Impacted mandibular third molar extraction is a common oral surgical procedure which is often attended by complications. Pain, trismus and swelling are commonly reported complications (28). The aforementioned consequences distress and negatively affect patients' life during the postoperative period. Therefore, there is a necessity for better pain, swelling and trismus control in patients who undergo third molar surgery.

In the present times, biological postoperative complication management measures are used. Platelet-rich fibrin (29) seems to have the ability to reduce postoperative swelling and pain, absorbable gelatin sponge (30) has been proven to effectively reduce bleeding. Furthermore, regarding recent years, evidence on the efficacy of biological materials such as drugs composed of herbal extracts (31) or proteolytic enzyme bromelain (32) in pain reduction after third molar removal surgery has emerged. However, allergies, the specificity of the methodology and additional fees limited these biological applications. Therefore, ways to optimize surgical procedures in clinical practice are being sought to ensure the good postoperative condition of the patient.

The influence of different wound closure methods in terms of pain, swelling, trismus, infection and healing time after third molar extraction was observed in the present review. However, clinical trials published in 2008 indicate a beneficial effect of a rubber drain on swelling and trismus (33). Previously discussed studies by M. S. Katz *et al.* (16) and Ting Hu *et al.* (17) did not find a significant effect on postoperative complication values after third molar removal. Lack of accuracy in previous studies could be a reason for contrasting results.

P. R. Cerqueira *et al.* (34) presented results claiming that the use of the tube drain helps to control swelling during the first postoperative days. These data match the findings of B.Kumar *et al.* (18), B.O.Koyuncu *et al.* (19), and Vishal *et al.* (20) who also presented significantly lower swelling results after surgery ($P \leq 0.05$). However, P.R. Cerqueira *et al.* (34) and other studies (18-20) also found a favorable effect on postoperative pain and trismus by using tube drain.

Different flap designs might lead to different results in terms of pain, trismus or swelling after third molar extraction. In this review (21, 22), two discussed studies investigated the effect of buccally and lingually based triangular flaps and their results found that buccally based triangular flap reduces postoperative pain, swelling and increases mouth opening. However, the results indicated by U. Yolcu and A. H. Acar (21) were not significant. Furthermore, it was concluded that a lingually based triangular flap reduces the incidence of wound dehiscence. Such

dehiscences could heal secondarily without any additional discomfort or may favour the development of alveolar osteitis or soft tissue abscesses as well as long-term discomfort (35).

Wound closure type after the removal of third molars also plays an important role in the occurrence of postoperative complications. Many studies (36-38) announced postoperative benefits of partial wound closure method compared to hermetical closure. P. K. Pachipulusu and S. Manjula (24) found that sutureless wound closure is significantly beneficial for patients in terms of pain and swelling after third mandibular molar extraction ($P < 0.002$). However, S.S. Nayak *et al.* (23) observed a significantly beneficial effect on swelling values ($P < 0.001$) and C.Gay-Escoda *et al.* (25) established no significant difference between hermetical closure and partial closure of the wound on swelling, pain, and trismus. It should be mentioned that the study by P.K.Pachipulusu and S.Manjula. (24) analyzed occlusal drainage pathway and other studies

Table 2. Articles included in the systematic review and overall findings

Reference No.	Author	Year of publication	Study methods/measures	Results
16	M. S. Katz <i>et al.</i>	2020	Rubber drain application	No significant effect of rubber drain insertion on swelling, pain, trismus or wound infections after third molar removal.
17	Hu, T. <i>et al.</i>	2017	Buccal and occlusal drain pathway	Buccal drainage accelerates wound healing and reduces postoperative bleeding; no significant differences in postoperative facial swelling or pain.
18	B. Kumar <i>et al.</i>	2016	Tube drain application	Tube drain significantly reduces postoperative swelling.
19	B. Ö. Koyuncu <i>et al.</i>	2015	Tube drain application	Tube drain significantly reduces postoperative swelling, pain and trismus.
20	Vishal <i>et al.</i>	2020	Tube drain application	Tube drain significantly reduces postoperative swelling and trismus.
21	Ü.Yolcu, A. H. Acar	2015	Lingually and buccally based triangular flap	No significant difference between the lingually based triangular flap and the traditional buccally based triangular flap on postoperative pain, swelling, trismus.
22	D. Menziletoglu <i>et al.</i>	2020	Lingually and buccally based triangular flap	Buccally based triangular flap reduces post-operative pain, swelling and increases mouth opening.
23	Sunil S. Nayak <i>et al.</i>	2020	Sutured and suture-less anterior releasing incision	Suture-less anterior releasing incision significantly reduces postoperative swelling.
24	P. K. Pachipulusu, S. Manjula	2018	Primary and secondary wound closure	Secondary wound closure is significantly beneficial in terms of postoperative pain and swelling.
25	C. Gay-Escoda <i>et al.</i>	2015	Hermetic closure and partial closure of the wound	No significant difference between hermetic closure and partial closure of the wound on swelling, pain, trismus.
26	R. Balamurugan and T. Zachariah	2019	Primary, secondary and closure with a buccal mucosal-advancement flap	Buccal mucosal-advancement flap significantly reduces pain, swelling and increases mouth opening.
27	Q. Xie <i>et al.</i>	2020	Modified envelope and modified triangular flap	Modified envelope flap significantly reduces swelling and increases mouth opening.

discussed (23, 25) were concerned with buccal drainage pathway. Secondary wound closure facilitates the drainage of inflammatory exudates after surgery and may potentially decrease postoperative pain, swelling and trismus. However, a partially closed socket may become contaminated by oral pathogens and food residue. Therefore, such conditions may lead to the development of potential alveolar osteitis.

In 2012 Z. H. Baqain *et al.* (39) compared triangular and envelope flap designs analysing postoperative complications. The study reported that envelope flap is superior to triangular flap in terms of post surgery swelling. Q. Xie *et al.* (27) also established the better effect of reduction of swelling in modified envelope flap on day 3 and 7 compared to the modified triangular flap ($P \leq 0.05$). R. Balamurugan and T. Zachariah (26) argued that postoperative pain, swelling and trismus could be reduced by using innovative buccal mucosal-advancement flap instead of primary or secondary wound closure. Although these methods provide promising results, more clinical studies with larger sample sizes evaluating these techniques ought to be investigated.

Furthermore, wound suture type might play a significant role in infection and postoperative discomfort after wisdom tooth removal. According to the results announced by A. H. Acar *et al.* (40), the horizontal mattress suturing technique is more effective in reducing wound infection rate compared to the interrupted suturing technique after impacted mandibular third molar extraction, although it does not decrease the values of pain, trismus and swelling.

Moreover, the application of antibacterial agents could also be beneficial in reducing postoperative consequences. S. Krishnan *et al.* (41) compared the

efficacy of triclosan or chlorhexidine impregnated sutures in preventing surgical wound infection after removal of the impacted mandibular third molars. The results of this study state that both triclosan and chlorhexidine coated sutures have an ability to prevent infection appearance. Although compared to triclosan sutures, chlorhexidine sutures were argued to minimize infection rates, erythema and trismus more efficiently in healthy patients, future studies with larger sample sizes should be investigated to assess the effect more accurately.

CONCLUSIONS

There was no significant effect of a rubber drain on swelling, pain, trismus, or wound infections after removal of the asymptomatic impacted third molar(s).

Tube drain insertion or modified envelope flap technique was observed to have a significant effect on swelling minimizing during the first post-surgery days.

Secondary wound closure was found to ensure lower pain, swelling and trismus ratio with comparison to primary wound closure. However, its use in clinical practice is limited due to the higher risk of infection.

The application of the buccally based triangular flap technique has been shown to provide less pain, trismus and swelling but also appears to display higher risk of wound dehiscence.

Buccal mucosal-advancement flap was found to have advantages regarding initial and partial closure while minimizing the disadvantages of both. It could have a beneficial effect in reducing postoperative pain, swelling, trismus and reducing the occurrence of infection.

REFERENCES

1. Scherstén E, Lysell L, Rohlin M. Prevalence of impacted third molars in dental students. *Swedish Dental Journal*. 1989 ;13(1-2):7-13.
2. Manoj Kumar S, Al-Hobeira H, Shaikh S, Siddiqui AA, Syed J, Mian RI, et al. Distribution of impacted third molars based on gender and patterns of angulation in dental students of the hai'l region, Saudi Arabia: A panoramic radiographic (OPG) study. *International Journal of Contemporary Medical Research*. 2017;4(9):1829-1832.
3. Hassan A. Pattern of third molar impaction in a Saudi population. *Clinical, Cosmetic and Investigational Dentistry*. 2010;:109.
4. Santos K, Lages F, Maciel C, Glória J, Douglas-de-Oliveira D. Prevalence of Mandibular Third Molars According to the Pell & Gregory and Winter Classifications. *Journal of Maxillofacial and Oral Surgery*. 2020;.
5. Khojastepour L, Khaghaninejad M, Hasanshahi R, Forghani M, Ahrari F. Does the Winter or Pell and Gregory Classification System Indicate the Apical Position of Impacted Mandibular Third Molars?. *Journal of Oral and Maxillofacial Surgery*. 2019;77(11):2222.e1-2222.e9.
6. McGrath C, Comfort M, Lo E, Luo Y. Changes in life quality following third molar surgery – the immediate postoperative period. *British Dental Journal*. 2003;194(5):265-268.
7. McArdle L, Andiappan M, Khan I, Jones J, McDonald F. Diseases associated with mandibular third molar teeth. *British Dental Journal*. 2018;224(6):434-440.
8. Güven O, Keskin A, Akal Ü. The incidence of cysts and tumors around impacted third molars. *International Journal of Oral and Maxillofacial Surgery*. 2000;29(2):131-135.
9. Natt Janakiraman E, Alexander M, Sanjay P. Prospective Analysis of Frequency and Contributing Factors of Nerve Injuries Following Third-Molar Surgery. *Journal of Craniofacial Surgery*. 2010;21(3):784-786
10. Bouloux G, Steed M, Perciaccante V. Complications of Third Molar Surgery. *Oral and Maxillofacial Surgery Clinics of North America*. 2007;19(1):117-128.
11. Contar C, Oliveira P, Kanegusuku K, Berticelli R, Azevedo-Alanis L, Machado M. Complications in third molar removal: A retrospective study of 588 patients. *Medicina Oral Patología Oral y Cirugía Bucal*. 2009;:e74-e78.

12. Deliverska E, Petkova M. Complications After Extraction Of Impacted Third Molars - Literature Review. *Journal of IMAB - Annual Proceeding (Scientific Papers)*. 2016;22(3):1202-1211.
13. Almendros-Marqués N, Berini-Aytés L, Gay-Escoda C. Influence of lower third molar position on the incidence of preoperative complications. *Oral Surgery, Oral Medicine, Oral Pathology, Oral Radiology, and Endodontology*. 2006;102(6):725-732.
14. Herrera-Briones F, Prados Sánchez E, Reyes Botella C, Vallecillo Capilla M. Update on the use of corticosteroids in third molar surgery: systematic review of the literature. *Oral Surgery, Oral Medicine, Oral Pathology and Oral Radiology*. 2013;116(5):e342-e351.
15. Morrow A, Dodson T, Gonzalez M, Chuang S, Lang M. Do Postoperative Antibiotics Decrease the Frequency of Inflammatory Complications Following Third Molar Removal?. *Journal of Oral and Maxillofacial Surgery*. 2018;76(4):700-708.
16. Katz M, Peters F, Elvers D, Winterhalder P, Kniha K, Möhlhenrich S et al. Effect of drain application on postoperative complaints after surgical removal of impacted wisdom teeth—a randomized observer-blinded split-mouth clinical trial. *Clinical Oral Investigations*. 2020;
17. Hu T, Zhang J, Ma J, Shao L, Gu Y, Li D et al. A novel method in the removal of impacted mandibular third molar: buccal drainage. *Scientific Reports*. 2017;7(1).
18. Kumar B, Bhate K, Dolas R, Kumar S, Wanknis P. Comparative Evaluation of Immediate Post-Operative Sequelae after Surgical Removal of Impacted Mandibular Third Molar with or without Tube Drain - Split-Mouth Study. *Journal of clinical and diagnostic research : JCDR*. 2016;vol. 10,12:46-49.
19. Koyuncu B, Zeytinoğlu M, Tetik A, Gomel M. Effect of tube drainage compared with conventional suturing on postoperative discomfort after extraction of impacted mandibular third molars. *British Journal of Oral and Maxillofacial Surgery*. 2015;53(1):63-67.
20. Vishal, Khaitan T, Ranjan R, Sharma N. Primary closure after surgical extraction of mandibular third molar with or without tube drain: A prospective study. *J Family Med Prim Care*. 2020;9(2):637-41.
21. Yolcu Ü, Acar AH. Comparison of a new flap design with the routinely used triangular flap design in third molar surgery. *Int J Oral Maxillofac Surg*. 2015;44(11):1390-7.
22. Menziletoglu D, Guler AY, Basturk F, Isik BK, Erdur EA. Comparison of two different flap designs for bilateral impacted mandibular third molar surgery. *J Stomatol Oral Maxillofac Surg [Internet]*. 2019;
23. Nayak SS, Arora A, Shah A, Sanghavi A, Kamath AT, Nayak VS. The influence of the suture-less anterior releasing incision in a triangular flap design on postoperative healing following surgical removal of impacted mandibular third molars. *J Int Soc Prev Community Dent*. 2020;10(3):262-8.
24. Pachipulusu PK, Manjula. Comparative study of primary and secondary closure of the surgical wound after removal of impacted mandibular third molars. *Oral Maxillofac Surg*. 2018;22(3):261-6.
25. Gay-Escoda C, Gómez-Santos L, Sánchez-Torres A, Herráez-Vilas J-M. Effect of the suture technique on postoperative pain, swelling and trismus after removal of lower third molars: A randomized clinical trial. *Med Oral Patol Oral Cir Bucal*. 2015;20(3):e372-7.
26. Balamurugan R, Zachariah T. Comparison of primary and secondary closure with a buccal mucosal-advancement flap on postoperative course after mandibular impacted third molar surgery. *Oral Maxillofac Surg*. 2020;24(1):37-43.
27. Xie Q, Wei S, Zhou N, Huang X. Modified envelope flap, a novel incision design, can relieve complications after extraction of fully horizontal impacted mandibular third molar. *J Dent Sci*. 2020;
28. Oginni FO, Ugboko VI, Assam E, Ogunbodede EO. Postoperative complaints following impacted mandibular third molar surgery in Ile-Ife, Nigeria. *SADJ*. 2002;57(7):264-8.
29. Canellas JV dos S, Ritto FG, Medeiros PJD. Evaluation of postoperative complications after mandibular third molar surgery with the use of platelet-rich fibrin: a systematic review and meta-analysis. *Int J Oral Maxillofac Surg*. 2017;46(9):1138-46.
30. Kim J-C, Choi S-S, Wang S-J, Kim S-G. Minor complications after mandibular third molar surgery: type, incidence, and possible prevention. *Oral Surg Oral Med Oral Pathol Oral Radiol Endod*. 2006;102(2):e4-11.
31. Isola G, Matarese M, Ramaglia L, Iorio-Siciliano V, Cordasco G, Matarese G. Efficacy of a drug composed of herbal extracts on postoperative discomfort after surgical removal of impacted mandibular third molar: a randomized, triple-blind, controlled clinical trial. *Clin Oral Investig*. 2019;23(5):2443-53.
32. Mendes MLT, do Nascimento-Junior EM, Reinheimer DM, Martins-Filho PRS. Efficacy of proteolytic enzyme bromelain on health outcomes after third molar surgery. Systematic review and meta-analysis of randomized clinical trials. *Med Oral Patol Oral Cir Bucal*. 2018;0-0.
33. Chukwunke FN, Oji C, Saheeb DB. A comparative study of the effect of using a rubber drain on postoperative discomfort following lower third molar surgery. *Int J Oral Maxillofac Surg*. 2008;37(4):341-4.
34. Cerqueira PRF, Vasconcelos BC do E, Bessa-Nogueira RV. Comparative study of the effect of a tube drain in impacted lower third molar surgery. *J Oral Maxillofac Surg*. 2004;62(1):57-61.
35. Şimşek Kaya G, Yapıcı Yavuz G, Saruhan N. The influence of flap design on sequelae and quality of life following surgical removal of impacted mandibular third molars: A split-mouth randomised clinical trial. *J Oral Rehabil*. 2019;46(9):828-35.
36. Osunde O, Adebola R, Saheeb B. A comparative study of the effect of suture-less and multiple suture techniques on inflammatory complications following third molar surgery. *International Journal of Oral and Maxillofacial Surgery*. 2012;41(10):1275-1279.
37. Damodar ND, Nandakumar H, Srinath NM. Postoperative recovery after mandibular third molar surgery: a criteria for selection of type of surgical site closure. *General Dentistry*. 2013 May-Jun;61(3):e9-e13.
38. Singh G, Gaur A, Mishra M, Mahesh C, Aurora JK, Gupta P. Comparative evaluation of primary and secondary closure after surgical removal of impacted mandibular third molar. *J Oral Maxillofac Surg Med Pathol*. 2014;26(2):133-7.
39. Baqain ZH, Al-Shafii A, Hamdan AA, Sawair FA. Flap design and mandibular third molar surgery: a split mouth randomized clinical study. *Int J Oral Maxillofac Surg*. 2012;41(8):1020-4.
40. Acar AH, Kazancıoğlu HO, Erdem NF, Asutay F. Is horizontal mattress suturing more effective than simple interrupted suturing on postoperative complications and primary wound healing after impacted mandibular third molar surgery? *J Craniofac Surg*. 2017;28(7):e657-61.
41. Krishnan S, Periasamy S, Murugaiyan A. Comparing the efficacy of triclosan coated sutures versus chlorhexidine coated sutures in preventing surgical site infection after removal of impacted mandibular third molar. *J Pharm Res Int*. 2020;138-48.

Received: 18 12 2019

Accepted for publishing: 21 12 2020