

The efficacy of short (6 mm) dental implants with a novel thread design

Soheil Bechara¹, Tatjana Nimčenko², Ričardas Kubilius³

SUMMARY

Objective. To assess efficacy of short (6 mm) implants with a novel macrostructure and thread design placed in a compromised bone situations of edentulous posterior regions of maxilla (3-4 mm of bone height under sinus floor) as compared to results of clinical situations treated with simultaneous maxillary sinus grafting and placement of long (≥ 10 mm) implants of the same company.

Study design. Clinical cases of conducted clinical study.

Patients and methods. Patients with compromised bone height in edentulous posterior regions of maxilla were randomly divided into two groups. Short (6mm length) implant treatment conducted in the test group and simultaneous sinus lift with standard length implant placement treatment in the control group.

Results. In general implant stability quotient (ISQ) and marginal bone level (MBL) changes values in both groups were comparable. However, significant negative correlation was found between implant's diameter and MBL changes.

Conclusions. Implant's length has little if none impact on initial implant anchorage, especially in greatly compromised residual bone situations. Results have confirmed that implant initial stability mainly depends on implant's macro-design and further its development on implant's micro-design: namely, implant diameter rather than length, tapered shape and improved thread design determines primarily acquired mechanical anchorage, while bioactive surface treatment ensures development of biological stability.

Key words: short implants, compromised residual bone height, implant diameter, implant stability quotient.

INTRODUCTION

Missing teeth may often result in a functional and cosmetic deficit and have been traditionally replaced with dentures or bridges. However, during the past decades implant therapy has been shown to be a successful option for tooth replacement, thus dental implants considered as an alternative to traditional solutions of dental arch rehabilitation. Dental implants inserted into the jawbones directly rely on the maintenance of structural and functional bone-to-implants surface connection that way supporting dental prosthesis. However, after tooth loss severely atrophic residual alveolar ridges are quite common

especially in patients who have been edentulous for a long period of time. Reduced alveolar bone height or presence of anatomical structures very often present a challenge to implant therapy usually in posterior areas of the maxilla and the mandible, as it is not possible to place dental implant of "adequate" length. In such cases clinician consider whether to use reconstructive surgical augmentation procedure to facilitate placement of implants of standard length (≥ 10 mm) (1) or to place short implants (having an intra-bony length of 5 to 8 mm (1, 2)). It is generally claimed that the best treatment in such situations is surgical modification of the patient's anatomy to place longer and wider implants. Although augmentation procedures have been well successful, they are more technically demanding and therefore require skillful operators. They are associated with significant postoperative morbidity and complications, are often more expensive and usually require more painful and longer healing times thus pro-

¹Mir Global, UAB, Vilnius, Lithuania

²Al Maha Dental Care, Doha, Qatar

³Clinical Department of Maxillofacial Surgery, Lithuanian University of Health Sciences, Kaunas, Lithuania

Address correspondence to Soheil Bechara, Tarptautinis implantologijos centras MIR, Kalvarijų g. 272A, LT-08339 Vilnius, Lithuania. E-mail address: info@mirklinika.lt

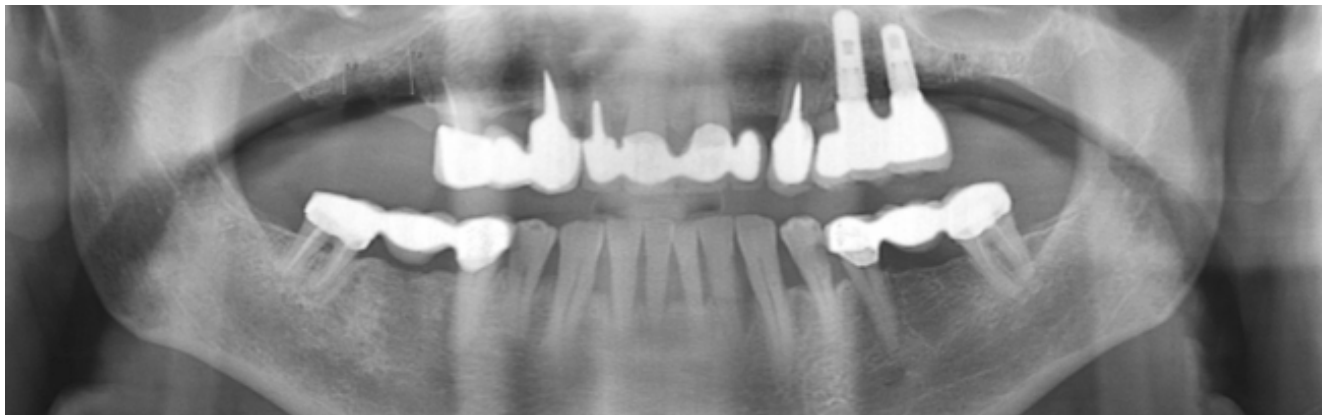


Fig. 1. 70 years old male patient enrolled to the short implants group

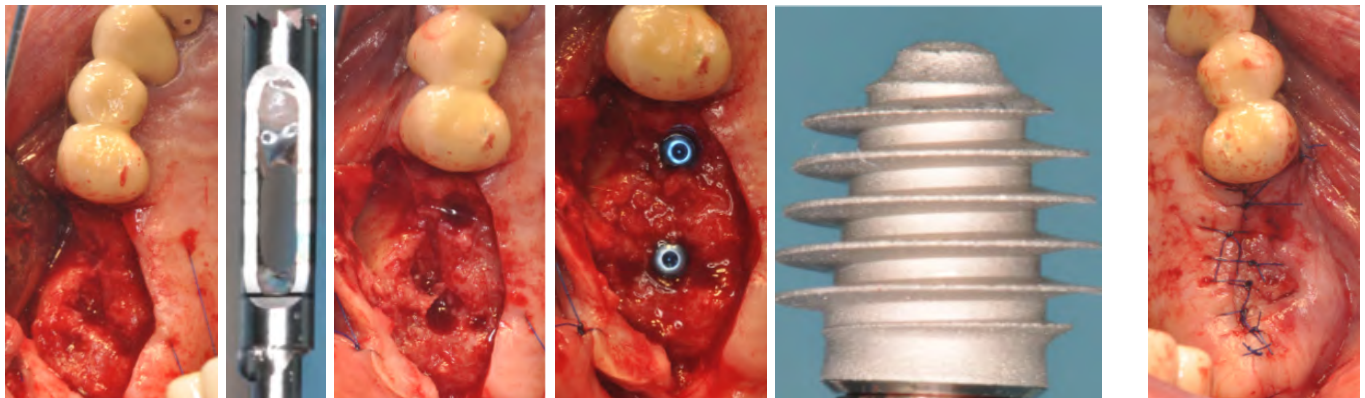


Fig. 2. Osteotomy performed with a single trephine drill “4.0 mm outer diameter”, and three implants 5.5×6 mm were inserted. Two of these implants were engaged 3-4 mm with the residual bone under the sinus.

longing overall treatment time before patients are able to chew on their implant-supported prosthesis (3, 4).

Placement of short dental implants thus adapting to the existing anatomy is an alternative treatment modality to bone grafting procedures as it avoids an invasive surgery at atrophic areas. It is known that differences in implant shapes (macro-design) induce significant changes in force distribution on the surrounding bone (5), therefore implant's modified design associated with surface treatment are the factors to compensate its short length. In relation to the regenerative techniques short implants show several advantages: lower cost and treatment length, simplicity, less risk of complications (6). Moreover, the development of the implant's design and surface, as well as surgical technique improvement lead to the reevaluation of the results and clinical studies have suggested that short implants provide similar outcomes to those reported for longer implants (1, 7-9). From the biomechanical point of view it is known that the crestal portion of the implant's body is the most involved in load-bearing and very little stress is transferred to the portion. Studies have shown, that increase of implants length has no positive effect on stresses transfer, whereas increased implant diameter reduced the intensity of stress along the length of the implant (10-12). Thus, the length of

the implant is no longer widely seen as the sole consideration when planning optimal treatment solution, as it is not the primary factor in distributing prosthetic loads to the bone-implant interface. As successful use of short implants (5 to 8 mm in length) fully engaged in bone is well documented in recent studies (1, 3, 6), therefore the aim of current implant practice is to prove efficacy of even shorter implant use in greatly resorbed bone cases.

The aim of this study was to assess efficacy of short (6 mm) implants with a novel macrostructure and thread design placed in a compromised bone situations of edentulous posterior regions of maxilla (3-4 mm of bone height under sinus floor) as compared to results of clinical situations treated with simultaneous maxillary sinus grafting and placement of long (≥ 10 mm) implants of the same company. In this article we present two clinical cases from our study of patients with edentulous posterior regions of maxilla treated according to surgical protocol of short or standard length implants.

MATERIAL AND METHODS

Present cases are based on the material of on-going research on efficacy evaluation of short

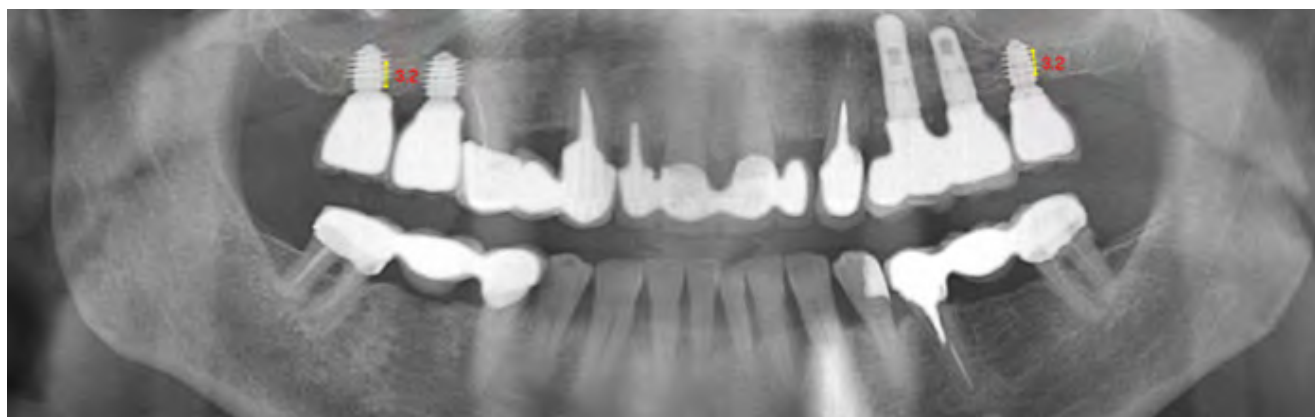


Fig. 3. Three years follow up panoramic X-ray showing a successful rehabilitation using short implants engaged only 3-4 mm in the residual bone under the sinus.

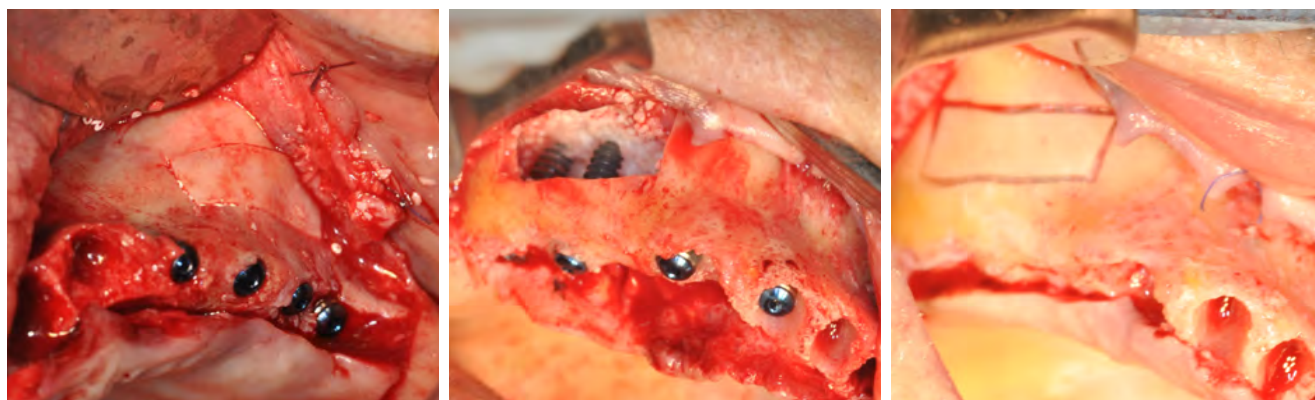

Fig. 4. Large sinus lateral sinus window was prepared using piezo-surgery device, the sinus membrane elevated and two 11.5mm long implants were inserted into the right sinus area. The implants reached respectively 69 and 71 ISQ value at insertion.

(6 mm) implants with a novel macrostructure and thread design engaged only 3-4 mm with bone. In this study comparative treatment plans were applied to patients with compromised clinical situations in posterior maxilla. Patients for the study were selected from all applying at Clinic of Oral and Maxillofacial Surgery (Lithuanian University of Health Sciences, Kaunas) for implant based mouth rehabilitation during the period from August 2010 to December 2013. The study included 88 implants and comprised of 53 patients (33 women and 20 men). According to the plan of the study patients were divided into two different groups randomly: first 45 implants were inserted simultaneously with sinus grafting and patients were assigned to control group. Other patients received 45 implants without grafting procedure and were assigned to the test group.

In both groups a noninvasive diagnostic method based on resonance frequency analysis was used to measure Implant Stability Quotient (ISQ) that indicates the level of stability and osseointegration in dental implants. Such measurements and peri-implant marginal bone level changes from radiographs were assessed immediately after implant insertion, before delivery of provisional restorations,

one and three years after loading. Obtained data was used to compare long-term results of both groups. In this article we present two clinical cases – one from each group.

Case report 1 (short implants – test group)

70 years old male patient presented with missing posterior teeth 16, 17 and 26 was enrolled to the short implants group (Figure 1). After evaluation of his pre-surgical CT scan three short (6mm) 5mm width Anyridge implants with internal conical morse-taper connection and deep sharp thread design (MegaGen Implant, Gyeongbuk, South Korea) were chosen for implantation according to clinical situation. A mucoperiosteal flap was raised and adapted surgical protocol according to the bone density was used. Drills with increasing diameters were used to prepare the implant sites. Implant sites were slightly underprepared and the motor was settled with a torque of 35 Ncm. No specific caution was taken to preserve the sinus membrane from perforation. Implants were placed, ISQ values measured and recorded, afterwards implants were submerged. Marginal gingival edges were adapted and sutured over the cover screws (Figures 2, 3). No grafting materials of any kinds were used. Im-

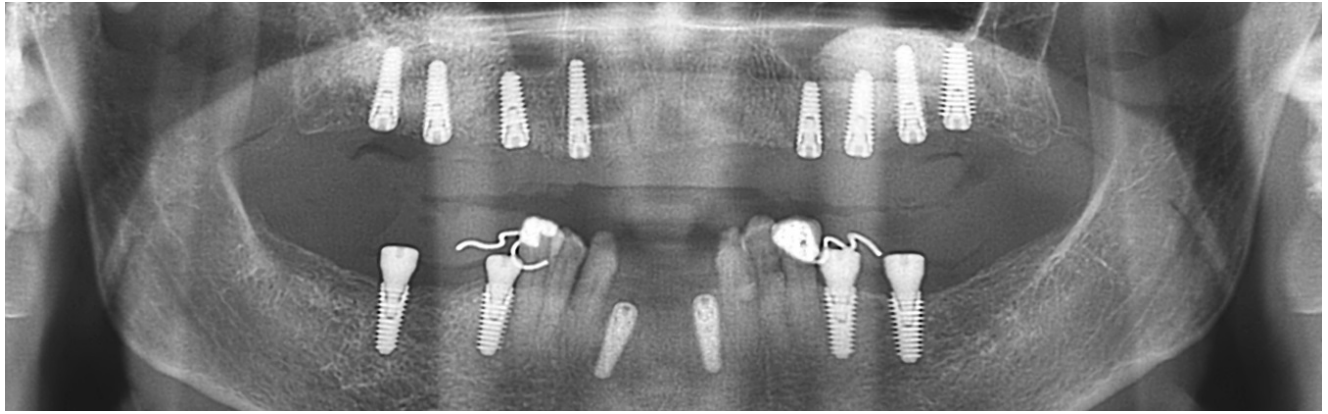


Fig. 5. On the left side, three implant inserted into the augmented sinus area, respectively 11.5, 15, and 13 mm in length

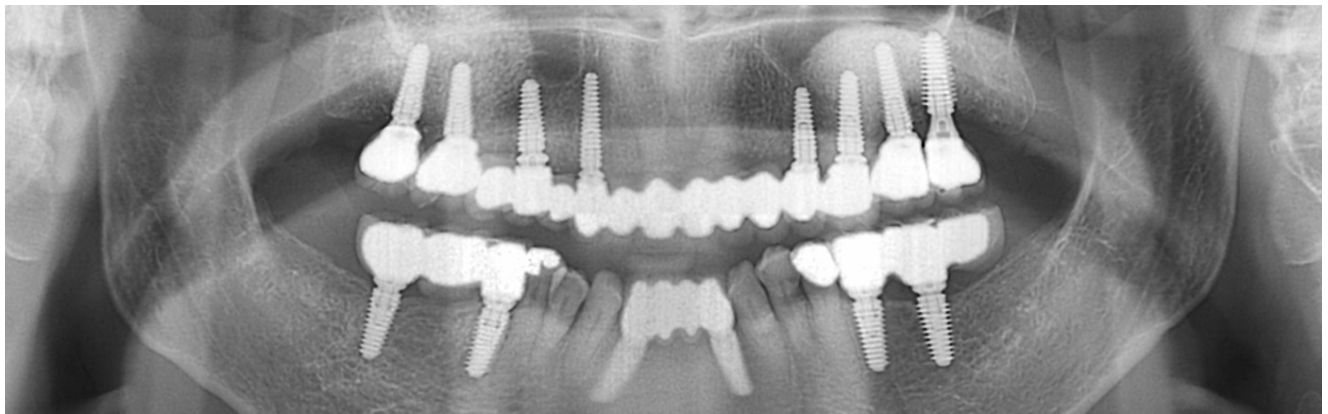


Fig. 6. Follow up panoramic X-ray after 3 years, showing successful rehabilitation

plants were loaded after 4 months with provisional acrylic prostheses and replaced after 4 months by final prostheses.

Case report 2 (standard length implants – control group)

A 63-year-old woman with edentulous maxilla was randomly referred to the control group. The patient had three implants previously placed (at the sites of upper right canine, upper right premolar and upper left canine) and wanted to avoid wearing removable prosthesis. Therefore, treatment plan based on clinical and radiographic (CT) evaluation included sinus lift procedures on both sides with immediate placement of 5 (2 on the right and 3 on the left side) standard length implants in posterior regions of maxilla. During operation sinuses were augmented following the lateral approach technique. After removal of a bony window, the maxillary membrane was carefully elevated and the sinus was packed with a particulate bone graft (Figure 4) (Oseobiol, GenOss), two standard length (>10 mm) implants (Megagen, Anyridge) of varying diameters (both 5 mm in diameter on the right, two of 4.5 mm and one of 5 mm in diameter on the left side) were inserted on both sides (according to previously

described adapted surgical protocol) and ISQ was evaluated. The maxillary window was then covered with a resorbable collagen barrier membrane (Ostobiol, Evolution) mucoperiosteal flap repositioned and sutured according to a submerged surgical protocol. The patient then was instructed to follow post-operative instructions. Implants were loaded 6 months after placement with provisional acrylic prostheses and replaced after 4 months by definitive prostheses (Figures 5, 6).

At each implant stability evaluation procedure (immediately after insertion, before provisional prosthesis delivery, 1 and 3 years after loading), prosthesis and abutments were removed and a metal rod (SmartPeg) of ISQ measuring equipment (“Ostell”, Gothenburg, Sweden) was screwed to implant, tightened. The transducer probe was then aimed at the top of small magnet of SmartPeg and held stable during pulsing time until ISQ value was displayed. Measurements were taken twice in both directions (buccolingual and mesiodistal). The mean off all measurements was rounded to whole numbers and regarded as ISQ of a certain implant. The abutments were then screwed back on the implants and tightened, provisionals were reinserted. Results were expressed as an implant stability quotient (ISQ),

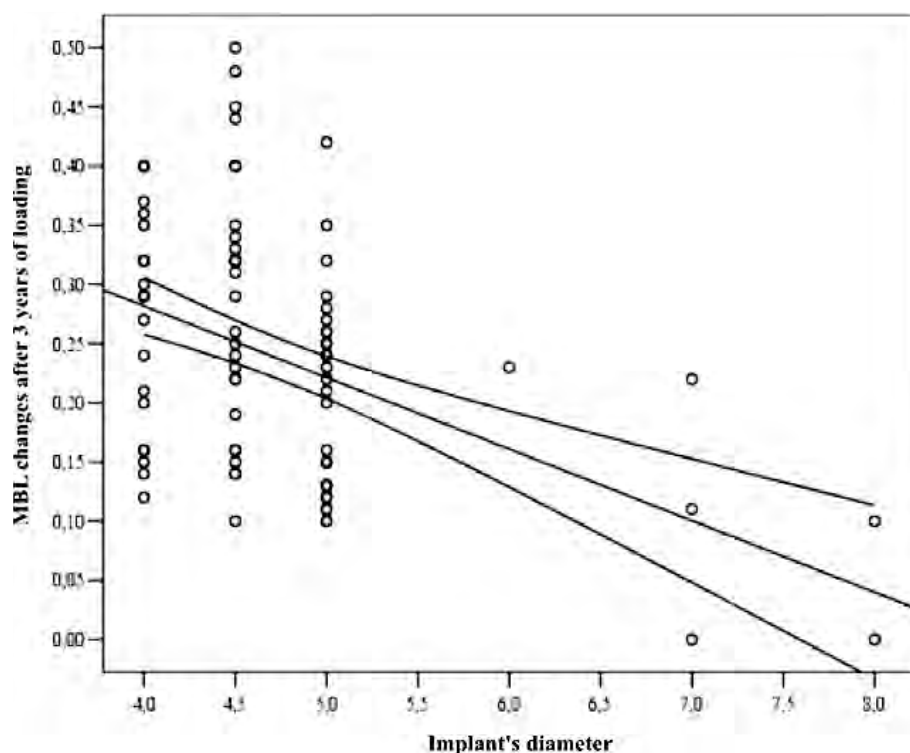


Fig. 7. Negative correlation between implant's diameter and MBL changes determined in the study after 3 years of loading

with values ranging from 1 (minimum stability) to 100 (maximum stability). Implants showing values <40 were considered failures.

Radiographs (taken immediately after implant placement, after delivery of provisionals, one and three years after loading) were studied for marginal bone level changes around implants: distances between marginal bone level and implant/abutment junction, approximated to half mm, were measured at both mesial and distal sides and averaged of every inserted implant. Bone level changes at single implants were averaged at patients level and then at group level. Radiographs were digitized in JPG, converted to TIFF format with a 600 dpi resolution, and stored in a personal computer. Peri-implant marginal bone levels were measured using the Scion Image (Scion Corporation, Frederick, MD, USA) software. The software was calibrated for every single image using the known distance of 2 consecutive treads. Measurements of the mesial and distal bone crest level adjacent to each implant were made to the nearest 0.01 mm. Reference points for the linear measurements were: the coronal margin of the implant collar and the most coronal point of bone-to-implant contact.

RESULTS

Treatment of both presented cases was successful and there were no implant failures or complications.

The ISQ measurements showed very similar results in both cases: all implants achieved adequate initial implant stability (>50 quotient units (QU)) that gradually increased within follow-up checks (Table 1). Moreover, these measurements matched results obtained in our clinical trial on efficacy evaluation of short (6mm) implants engaged 3-4mm with bone where they were compared to standard length implants: initial mean ISQ of the sample was 68 (SD=3.9), mean in the control 66.8 (3.4) and in the test group 69.1 (4.1), the difference between two groups being significant as $p=0.003$. A notable increase over time was observed in the sample (mean 4 (1.8) QU, $p=0.001$) and within groups (control group mean

increase 4.6 (1.9) QU, $p=0.000$; test group mean increase 3.2 (1.4) QU, $p=0.000$).

Marginal bone level (MBL) changes

Evaluation of marginal bone level (MBL) changes around inserted implants showed the major marginal bone resorption in both cases occurred during first year of loading and was less obvious during second and third years (Table 2). These results also correspond to ones obtained in our research: in the sample significant resorption occurred only during first year of loading (0.18 (0.09) mm, $p=0.017$) whereas later changes were less noticeable (0.06 (0.04) mm, $p=0.5$) and significant difference was found between mean marginal bone resorption during first year of loading and later ($p=0.000$).

Moreover, in presented cases greater resorption was determined around implants of smaller diameter (4 mm) (Table 2). The same trends were observed in our research: a significant strong negative correlation ($\rho=-0.432$, $p=0.000$) between MBL changes during 3 years loading period and implant's diameter was found as in cases with wider implants (≥ 4.5 mm) a more sustainable marginal bone level was achieved avoiding later significant bone resorption (Figure 7).

DISCUSSION

Since nowadays treatment is aimed towards simplified, viable and successful methods that lead

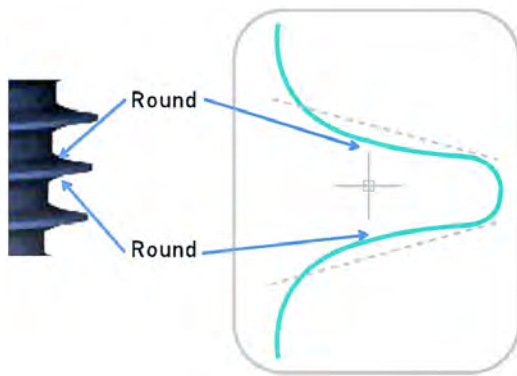


Fig. 8. Anyridge implant thread design

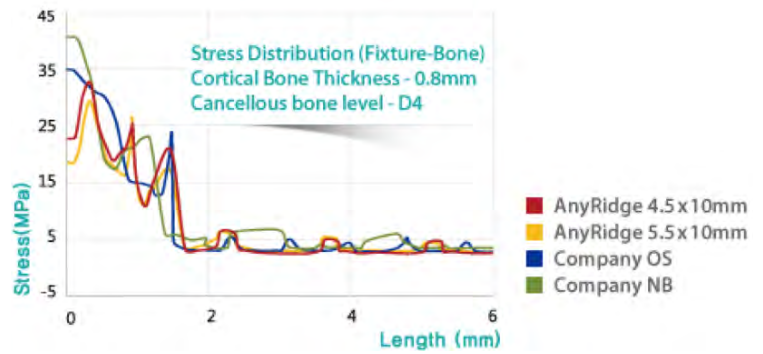


Fig. 9. Stress distribution in alveolar bone along implants

to greater case acceptance for the patient, the use of short implants becomes more and more acceptable. Recent researches (13-15) lead to the conclusion that the success and survival rates for short implants as short as 6 mm in length are similar to those of longer implants and demonstrate the importance of appropriate macro-geometric design for short implants. Thus, presented study was anticipated to expand boundaries of current implant practice and was designed to evaluate whether 6 mm long implant engaged in bone only 3-4 mm could be an alternative treatment for the rehabilitation of posterior atrophic maxilla as effective as traditional approach

of compromised situations using standard-length implants (≥ 10 mm) placed simultaneously with lateral sinus augmentation. In our study new implants of the same company with a novel macrostructure and deep thread design were used in both control and test groups allowing a more direct comparison between two procedures. These implants have been reported to demonstrate good clinical results as special thread design increases bone-implant contact (BIC) and primary stability dramatically, having a large surface area in contact with bone even in very low alveolar ridges. As three-dimensional bond between bone and implant is achieved the bone in-growth between the threads increase the implant resistance to occlusal and shear forces (16), therefore such features were expected to favor results when implants engaged only 3-4mm in bone.

Our research was based on the use of modified surgical protocol and special thread design (assuring increased BIC achievement) to obtain initial anchorage of short implants that would warrant stable long-term results without the need of additional bone inducement. Evaluation of the measurements showed that all implants of the research sample achieved adequate initial anchorage, which is generally considered acceptable (initial ISQ values were > 58 QU). Overall ISQ increase during investigation period was significant ($p=0.001$) with a mean value of 4 (1.8) quotient units (QU) in the sample with a

Table 1. ISQ changes of short and standard length implants placed in compromised bone situations

	Short implants (test) group		Standard length implants (control) group				
	6x5	6x5	11x4	11x4	11.5x4	15x4.5	13x5
Implants (length× width) mm	6x5	6x5	11x4	11x4	11.5x4	15x4.5	13x5
Initial ISQ (QU)	69	69	66	66	66	67	69
ISQ at provisional prosthesis delivery	70	70	67	67	67	68	70
ISQ at 1 year after loading	71	71	67	68	68	69	71
ISQ at 3 years after loading	72	71	68	68	69	70	72

Table 2. MBL changes of presented clinical cases

	Short implants (test) group		Standard length implants (control) group				
	6x5	6x5	11x4	11x4	11.5x4	15x4.5	13x5
Implants (length× width) mm	6x5	6x5	11x4	11x4	11.5x4	15x4.5	13x5
MBL change during first year of loading (mm)	0.14	0.13	0.22	0.22	0.21	0.20	0.14
MBL changes after II, III years of loading (mm)	0.05	0.04	0.07	0.06	0.06	0.07	0.04
Overall MBL change after 3 years of loading (mm)	0.19	0.17	0.29	0.28	0.27	0.27	0.18

substantial increase of ISQ during the first year of loading most likely due to load induced bone density increase. Moreover, no dip in implant stability has been observed that is generally considered to occur between the second and eight weeks following implant placement (17-19). This could be explained by features of bioactive surface of implants that accelerates formation of BIC and contributes to faster increase in biological stability. This biologic process compensates for any decrease of mechanical stability and ensures consistency in stability over time, without the drop during the healing period (20, 21). When comparing intergroup results significant difference ($p < 0.05$) was found with ISQ increase being higher in the control (sinus augmented) group as was expected due to bone graft material remodeling and osseointegration developing an increased BIC.

The design of used implants could have also favorably affected the results as it was estimated in many researches that implant design has a greater impact on functional surface area than implant size (22, 23). A threaded implant design may have some bone present in the depth of the threads from the day of insertion. Implants that were used in this research have deep, knife-shaped threads that were designed to increase cutting efficiency during insertion and thereby initial stability. Their design features do not require integration to resist even immediate loads and have greater surface area to resist occlusal forces when compared to Brånemark compatible implants. The number, spacing and orientation of the threads also affect the amount of area available to resist the forces during loading. The greater the number

of threads, the greater the functional surface area. The smaller the distance between the threads, the greater the thread number and corresponding surface area (22, 24). The majority of implants used in this study were of >4.5 mm in diameter and their pitch is 0.8 mm, in comparison to 1.2-1.6 mm pitch of Brånemark compatible implants of similar diameter (25-27). Another influencing feature is thread depth, which is also variable in implant design. The greater the thread depth, the greater the functional surface area. Therefore, the thread depth of implants mainly used in this study varied from 0.35 mm (for 4 mm diameter implants) to 0.85 (for 5 mm diameter implants) in comparison to 0.32-0.43 mm similar diameter Brånemark implants. Hence, the threaded implant may have more than 2 times the overall functional surface area, when compared with other implants of similar length and width (25-28). Moreover, the thread geometry may affect the strength of early osseointegration and the BIC. For a "V" shaped thread design, a 10 times greater shear force is applied to bone compared with a square thread shape (23, 24, 26). As bone is strongest in compressive and weakest in shear loading, compressive force transfer of square thread shape implant decrease the microstrain to bone and subsequently decrease crestal bone overload after implant is integrated (22, 24, 29). Sharp, square – shaped rounded threads (Figure 8) of used Anyridge implants are considered to increase resistance to compressive forces and minimize occurrence of shear forces (16). One more advantage of used implants in this research is their increased surface area (Table 3, 4). For example, the length of the implant in most systems increases in increments of 2 to 4 mm. Each 3 mm increase in length can increase surface area by approximately 20% for a cylinder implant design (as Brånemark compatible implants). Anyridge implants have modified thread design and tapered geometry, therefore the widest part of implant is 3.5 mm below implant's platform and first 3-4 mm (from the platform) of implant length greatly increase surface area. Consequently Anyridge implants of 4 to 5 mm diameter engaged in bone 3-4 mm initially have similar BIC (contacting surface area) when compared to Brånemark implants of similar diameter engaged 7 mm in bone.

Table 3. Anyridge implant surface area corresponding to implant's length (from the platform) engaged in bone

Length/ diameter	4.0 Anyridge (mm ²)	4.5 Anyridge (mm ²)	5.0 Anyridge (mm ²)
3	64	83	103
4	79	105	132
5	94	126	160
6	108	146	187
7	121	165	213
8.5	141	195	254
10	152	207	269

Table 4. Cylindrical implant surface area (Misch 2004)

Length (mm)/ diameter (mm)	3.0	3.5	4.0
7	73	87	100
10	100	118	135
13	129	152	176

Implant diameter influence on MBL changes

As one of the criteria for implant success, stable bone levels are believed to be critical to the long term maintenance of an implant (30). Evaluation of MBL changes in 3 years after loading in this study was performed regarding bone levels at prosthesis delivery as baseline data. Research showed that major mean bone

resorption around implants occurred during the first year of loading and less noticeable during later years. Moreover, in our study negative relation was determined between MBL changes during loading period and implant's diameter. Such findings coincide with clinical researches stating that stress level in the bone can be efficiently reduced using wider implants (10, 31). Apparently, wider implants contribute to a more favorable stress distribution in the bone around implant, thus conditioning less marginal bone resorption.

In our study no significant correlation between implant's length and MBL changes was found when comparing results of short and standard length implants groups. Therefore, it may be assumed that implant length engaged in alveolar bone seems not to influence the degree of bone resorption around implant after a medium-term period of 3 years. Moreover, these data compare favorably with those reported in similar researches (30-35). The low degree of marginal bone remodeling in the present study may be also related to the implant design. Numerous studies confirm that implant length does not influence bone stress location. Whatever the implant length, the stress usually is located at the implant neck level in the cortical bone layer, thus beyond the 3 cervical millimeters the stress intensity is low (10, 36, 37) (Figure 9). Therefore, the exclusive features of our used implants might have helped to reduce the crestal bone loss. The widest area of these tapered-form implants, which due to mechanical contact with bone determines primary stability of the implant, is about 3.5 mm beyond implant's platform and corresponds to the fourth thread. Implant part above this area is relatively narrower due to comparatively narrow implant body and consequently narrow implant neck. Deep rounded knife threads increase cutting efficiency during insertion thus lower insertion torque is needed and the crestal cortical layer is maintained ensuring load-bearing capacity at the implant neck. Implants macro-design also

contributes to higher initial stability, resistance to compressive forces and occurrence of shear forces. Even stress distribution ensuring implant design and maintenance of more undamaged cortical layer possibly contributed to more stable marginal bone in our study. In addition, the absence of specific crestal bone loss after loading showed that a limited amount of supporting bone is capable of withstanding the expected posterior occlusal stresses.

CONCLUSIONS

Presented cases from our study demonstrate comparable efficacy of short (6 mm) implants in a compromised bone situations of edentulous posterior regions of maxilla (3-4 mm of bone height under sinus floor) to results of clinical situations treated with simultaneous maxillary sinus grafting and standard length (≥ 10 mm) implants of the same company. Presented study evidenced, that implant's length has little if none impact on initial implant anchorage, especially in greatly compromised residual bone situations. Results have confirmed studies of other authors that implant initial stability in compromised situations mainly depends on implant's macro-design and further its development on implant's micro-design: namely, implant diameter rather than length, tapered shape and improved thread design determines primarily acquired mechanical anchorage, while bioactive surface treatment ensures development of biological stability. Short implants (6 mm) with improved design and modified operation protocol offer a promising alternative to standard treatment methods in compromised clinical situations with similar outcomes after 3 years of function, although the short implant treatment takes considerably less operation time with decreased surgical complications and postoperative patient discomfort compared to sinus augmentation procedures with simultaneous standard-length implant placement.

REFERENCES

1. Renouard F, Nisand D. Impact of implant length and diameter on survival rates. *Clin Oral Implants Res* 2006;17 Suppl 2:35-51.
2. Esposito M, Coulthard P, Thomsen P, Worthington HV. The Role of implant surface modifications, shape and material on the success of osseointegrated dental implants. A Cochrane systematic review. *Eur J Prosthodont Restor Dent* 2005;13:15-31.
3. Esposito M, Worthington HV, Coulthard P, Jokstad A. Interventions for replacing missing teeth: maintaining and re-establishing healthy tissues around dental implants. *Cochrane Database Syst Rev* 2002;3:CD003069.
4. Esposito M, Grusovin MG, Felice P, Karatzopoulos G, Worthington HV, Coulthard P. The Efficacy of horizontal and vertical bone augmentation procedures for dental implants - a Cochrane systematic review. *Eur J Oral Implantol* 2009;2:167-84.
5. Chun HJ, Cheong SY, Han JH, Heo SJ, Chung JP, Rhyu IC, et al. Evaluation of design parameters of osseointegrated dental implants using finite element analysis. *J Oral Rehabil* 2002;29:565-74.
6. Felice P, Marchetti C, Iezzi G, Piattelli A, Worthington H, Pellegrino G, et al. Vertical ridge augmentation of the atrophic posterior mandible with interpositional bloc grafts: bone from the iliac crest vs. bovine anorganic bone. Clinical and histological results up to one year

- after loading from a randomized-controlled clinical trial. *Clin Oral Implants Res* 2009;20:1386-93.
7. Deporter DA, Todescan R, Caudry S. Simplifying management of the posterior maxilla using short, porous-surfaced dental implants and simultaneous indirect sinus elevation. *Int J Periodontics Restorative Dent* 2000;20:476-85.
 8. Stellingsma K, Bouma J, Stegenga B, Meijer HJ, Raghoebar GM. Satisfaction and psychosocial aspects of patients with an extremely resorbed mandible treated with implant-retained overdentures: a prospective, comparative study. *Clin Oral Implants Res* 2003;14:166-72.
 9. Fugazzotto PA, Beagle JR, Ganeles J, Jaffin R, Vlassis J, Kumar A. Success and failure of 9 mm or shorter implants in the replacement of missing maxillary molars when restored with individual crowns: preliminary results 0 to 48 months in function. A retrospective study. *J Periodontol* 2004;75:327-32.
 10. Pierrisnard L, Renouard F, Renault P, Barquins M. Influence of implant length and bicortical anchorage on implant stress distribution. *Clin Implant Dent Rel Res* 2003;5:254-62.
 11. Birdi H, Schulte J, Kovacs A, Weed M, Chuang SK. Crown-to-implant ratios of short length implants. *J Oral Implantol* 2010;36:425-33.
 12. Petrie CS, Williams JL. Comparative evaluation of implant designs: Influence of diameter, length and taper. on strains in the alveolar crest. A three-dimensional finite-element analysis. *Clin Oral Implants Res* 2005;16:486-94.
 13. Anner R, Better H, Chaushu G. The clinical effectiveness of 6 mm diameter implants. *J Periodontol* 2005;76:1013-5.
 14. Fugazzotto PA. Shorter implants in clinical practice: rationale and treatment results. *Int J Oral Maxillofac Implants* 2008;23:487-96.
 15. Arlin ML. Short dental implants as a treatment option: results from an observational study in a single private practice. *Int J Oral Maxillofac Implants* 2006;21:769-76.
 16. Bechara S, Park KB, Kubilius R, Lukošiusas A. New possibilities – avoiding bone grafting with short implants. *Implant Dent Today* 2012;6:17-20.
 17. Balshi SF, Allen FD, Wolfinger G, Balshi TJ. A resonance frequency analysis assessment of maxillary and mandibular immediately loaded implants. *Int J Oral Maxillofac Implants* 2005;20:584-94.
 18. Lai HC, Zhang ZY, Wang F, Zhuang LF, Liu X, Pu YP. Evaluation of soft-tissue alteration around implant-supported single-tooth restoration in the anterior maxilla: the pink esthetic score. *Clin Oral Implants Res* 2008;19:560-4.
 19. Glauser R, Schüpbach P, Gottlow J, Hämmerle CH. Periimplant soft tissue barrier at experimental one-piece mini-implants with different surface topography in humans: A light-microscopic overview and histometric analysis. *Clin Implant Dent Relat Res* 2005;7(Suppl 1):S44-51.
 20. Strnad J, Urban K, Povysil C, Strnad Z. Secondary stability assessment of titanium implants with an alkali-etched surface: a resonance frequency analysis study in beagle dogs. *Int J Oral Maxillofac Implants* 2008;23:502-12.
 21. Ellingsen JE, Johansson CB, Wennerberg A, Holmén A. Improved retention and bone-to-implant contact with fluoride-modified titanium implants. *Int J Oral Maxillofac Implants* 2004;19:659-66.
 22. Misch CE, Steigenga J, Barboza E, Misch-Dietsch F, Cianciola LJ. Short dental implants in posterior partial edentulism: a multicenter retrospective 6-year case series study. *J Periodontol* 2006;77:1340-7.
 23. Steigenga JT, al-Shammari KF, Nociti FH, Misch CE, Wang HL. Dental implant design and its relationship to long-term implant success. *Implant Dent* 2003;12:306-17.
 24. Misch C. Complications of autogenous bone grafting. In: *Dental implant complications: etiology, prevention and treatment*. Ed by SJ Froum. Wiley-Blackwell; 2010.
 25. Chiapasco M, Abati S, Romeo E, Vogel G. Implant-retained mandibular overdentures with Brånemark System MKII implants: a prospective comparative study between delayed and immediate loading. *Int J Oral Maxillofac Implants* 2001;16:537-46.
 26. Horiuchi K, Uchida H, Yamamoto K, Sugimura M. Immediate loading of Brånemark system implants following placement in edentulous patients: a clinical report. *Int J Oral Maxillofac Implants* 2000;15:824-30.
 27. Randow K, Ericsson I, Nilner K, Petersson A, Glantz PO. Immediate functional loading of Brånemark dental implants. An 18-month clinical follow-up study. *Clin Oral Implants Res* 1999;10:8-15.
 28. Tarnow DP, Emtiaz S, Classi A. Immediate loading of threaded implants at stage 1 surgery in edentulous arches: ten consecutive case reports with 1- to 5-year data. *Int J Oral Maxillofac Implants* 1997;12:319-24.
 29. Sagara M, Akagawa Y, Nikai H, Tsuru H. The effects of early occlusal loading on one-stage titanium alloy implants in beagle dogs: a pilot study. *J Prosthet Dent* 1993;69:281-8.
 30. Venuleo C, Chuang S-K, Weed M, Dibart S. Long term bone level stability on short implants: a radiographic follow up study. *J Maxillofac Oral Surg* 2008;7:340-5.
 31. Akça K, Iplikçioğlu H. Finite element stress analysis of the effect of short implant usage in place of cantilever extensions in mandibular posterior edentulism. *J Oral Rehabil* 2002;29:350-6.
 32. Bornstein MM, Chappuis V, von Arx T, Buser D. Performance of dental implants after staged sinus floor elevation procedures: 5-year results of a prospective study in partially edentulous patients. *Clin Oral Implants Res* 2008;19:1034-43.
 33. Fermergard R, Astrand P. Osteotome sinus floor elevation without bone grafts - a 3-year retrospective study with Astra Tech implants. *Clin Implant Dent Relat Res* 2012;14:198-205.
 34. Weber HP, Buser D, Fiorellini JP, Williams RC. Radiographic evaluation of crestal bone levels adjacent to nonsubmerged titanium implants. *Clin Oral Implants Res* 1992;3:181-8.
 35. Laurell L, Lundgren D. Marginal bone level changes at dental implants after 5 years in function: a meta-analysis. *Clin Implant Dent Relat Res* 2011;13:19-28.
 36. Meijer, Steen W, Bosman F. A comparison of methods to assess marginal bone height around endosseous implants. *J Clin Periodontol* 1993;20:250-53.
 37. Hedia HS. Effect of coating thickness and its material on the stress distribution for dental implants. *J Med Eng Technol* 2007;31:280-7.

Received: 14 07 2014
Accepted for publishing: 28 06 2017