

# Evaluation of bone mineral density in postmenopausal women with alterations of the mandible cortical bone

*Estera Miliuniene<sup>1</sup>, Vidmantas Alekna<sup>2</sup>, Vytaute Peciuliene<sup>1</sup>, Marija Tamulaitiene<sup>2</sup>*

## SUMMARY

**Objective.** Menopause affects the bone quality and quantity of jaw bone. The aim of this study was to evaluate the validity of mandibular cortical measurements in the diagnosis of low bone mineral density (BMD) in postmenopausal women.

**Methods.** A total of 113 postmenopausal women (mean age 63.15±6.05 years), living in Lithuania, were examined. Participants were categorized as either normal BMD, or low BMD according to the WHO classification in relation to their spine BMD determined by dual energy X-ray absorptiometry. None of the participants were known to have endocrine, metabolic or skeletal disorders. BMD was measured in the spine lumbar area L2-L4. The mandibles were examined on panoramic x-ray images. The following radiomorphometric indices were measured: the height of the mandibular inferior cortex below *foramen mentalae* (IC) and cortical thickness at the angle of the mandible (Panoramic Angular Index (PA)). Receiver operating characteristics (ROC) curve analysis was used to determine the validity of cortical measurements in the diagnosis of low BMD obtained and the area under the ROC curve (AUC) was calculated.

**Results.** Significant associations were found between IC and PA, and low BMD. The areas under the ROC (AUC) of PA was 0.753 (95% CI, 0.645-0.861) and of IC was 0.709 (95% CI, 0.601-0.816). High levels of intra- and interobserver agreement were demonstrated.

**Conclusions.** Postmenopausal women with spinal low BMD can be identified moderately accurately by mandibular cortical findings.

**Key words:** menopause, mandible, cortical bone, bone mineral density.

## INTRODUCTION

Osteoporosis is a systemic disease characterized by reduced bone mass and a thinning of the trabecular architecture. This condition often leads to increased bone fragility and subsequent fracture (1, 2). A primary cause of osteoporosis is related to a drop of estrogen levels in blood after menopause (1). Mainly it affects women and results in more rapid bone loss (2) as well as affects the quality and quantity of the jaw bone (3). Due to the fact that symptoms of this disease are rare till fracture occurs, therefore diagnosis of it usually is late. The consequences of osteoporosis in the mandible are loss in height of the alveolar bone, erosion of inferior mandibular cortex, reduced percentage of

mandibular cortical bone, reduction of bone BMD values of mandibular trabecular bone (1, 3-6, 10).

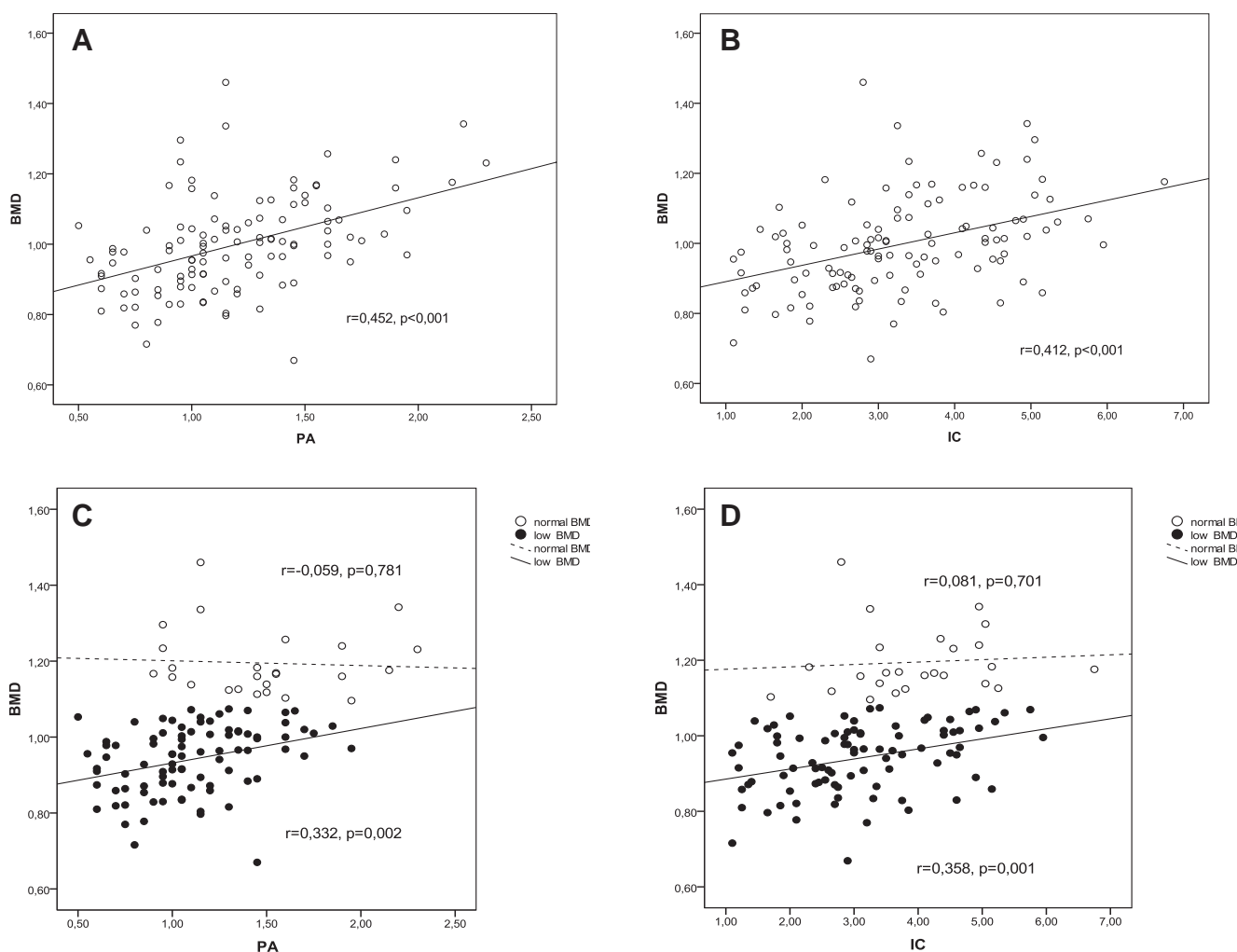
Results of the studies have demonstrated the negative correlation between BMD of lumbar spine and cortical bone height of mandible below the *foramen mentalae* and at the angle of the mandible, and the usefulness of cortical indices, such as cortical width and shape determined from panoramic radiographs (5, 6, 15). Such findings allowed identify individuals with undetected low skeletal BMD or osteoporosis, especially in postmenopausal women. However Munakata *et al.* observed no correlation between BMD and bone width of the mandible in the postmenopausal women (3).

Dual-energy X-ray absorptiometry (DXA) is the most commonly used technique in measuring BMD in the hip or spine and it is a gold standard for the diagnosis of osteopenia/osteoporosis at the spine and/or hip, however until now it has been used solely in experimental settings, for jaw bone evaluation (7-9). Due to the fact that osteoporosis is a widespread problem, there is an ongoing dis-

<sup>1</sup>Institute of Odontology, Faculty of Medicine, Vilnius University, Lithuania

<sup>2</sup>Institute of Experimental and Clinical Medicine at Vilnius University, Faculty of Medicine, Vilnius University, Lithuania

Address correspondence to Estera Miliuniene, Institute of Odontology, Faculty of Medicine, Vilnius University, Zalgirio str.117, LT-08217 Vilnius, Lithuania.  
E-mail address: estera.miliuniene@mf.vu.lt



**Fig. 1.** Relationship between BMD and PA, IC in normal, low and total BMD groups. A – relationship between BMD and PA in total group (n=113). B – relationship between BMD and IC in total group (n=113). C – relationship between BMD and PA in low BMD (n=88) and normal BMD (n=25) group. D – relationship between BMD and IC in low BMD (n=88) and normal BMD (n=25) group.

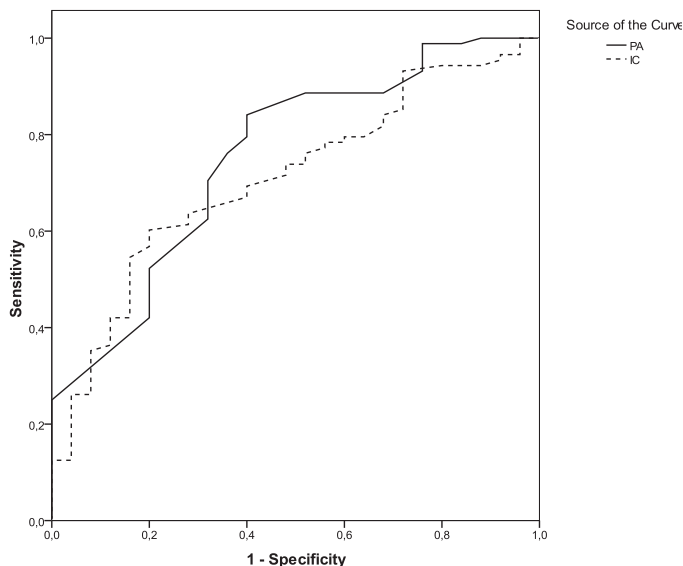
discussion of the benefit of a preventative screening. Since DXA is not routine technique in measuring mandible BMD, meanwhile the panoramic radiographs which are routinely taken in general dental practice could become helpful method to assess the jaw bone. The goal of this study is to determine the validity of mandible cortical measurements in the diagnosis of low BMD.

## MATERIALS AND METHODS

The participants of the study were unselectively recruited women volunteers who had attended a dental clinic for general basic dental care. From 137 women who were invited to participate in the study, 135 accepted the invitation. From 135 eligible women 113 women were examined. Other 42 women did not arrive for examination either had been not included to the study regarding to the exclusion criteria. The inclusion criteria were females in their postmenopausal stage (no menstruation for at

least 6-12 months). The exclusion criteria were any endocrine and metabolic bone disease (hyperparathyroidism, hypoparathyroidism, Paget's disease, osteomalacia, renal osteodystrophy or osteogenesis imperfecta), cancer with bone metastasis, significant renal impairment, history of taking medication known to affect bone metabolism (e.g. estrogen), undergone hysterectomy or oophorectomy, history of smoking, any bone destructive lesion (e.g. malignant tumours or osteomyelitis) in the mandible, any spinal fracture, present treatment for osteoporosis (14, 15).

The Ethical Committee of Vilnius University Faculty of Medicine Institute of Odontology approved the study protocol (2004-01-08, Nr.1). Written informed consent was obtained from each participant in order to perform panoramic radiography and bone densitometry. The mandibles were examined on panoramic images taken with a radiographic apparatus ORTHOPHOS 3 (Sirona, Germany) by a single operator. Measurements of



**Fig. 2.** Receiver operating characteristics (ROC) curve for identifying postmenopausal women with low BMD by IC (dotted arrow) and PA (solid arrow)

the height of mandible and the width of cortex were made using a digital vernier caliper with an LCD display screen and technical specifications of resolution 0.01 mm, power 1-1.5 V button cell. A special magnification loupe with frames (SDI, Sweden) creating a dark setting was used. On the both sides of mandible successive measurements were recorded: the height of the Mandibular Inferior Cortex below *foramen mentalae* (IC) (12) and cortical thickness at the angle of the mandible (Panoramic Angular Index (PA)) (13). IC and PA measurements were located bilaterally and the values were used as the average of the measurements at these two points.

**Table 1.** Sample characteristics: T-score, BMD, PA, IC, the age when menopause began, years after menopause

Sample characteristics	Mean Score $\pm$ SD			p
	Total (n=113)	Normal BMD (n=25)	Low BMD (n=88)	
T-score	-1.61 $\pm$ 1.15	0.05 $\pm$ 0.73	-2.08 $\pm$ 0.74	<0.001
BMD	0.997 $\pm$ 0.138	1.195 $\pm$ 0.088	0.941 $\pm$ 0.089	<0.001
PA	1.19 $\pm$ 0.38	1.48 $\pm$ 0.41	1.10 $\pm$ 0.32	<0.001
IC	3.29 $\pm$ 1.22	3.97 $\pm$ 1.11	3.09 $\pm$ 1.19	0.001
Age when menopause began	50.39 $\pm$ 4.93	49.45 $\pm$ 5.33	50.66 $\pm$ 4.81	0.282
Years after menopause	12.76 $\pm$ 6.75	11.82 $\pm$ 8.37	13.02 $\pm$ 6.24	0.436

**Table 2.** Correlations between PA, IC indices and BMD

Index	Normal BMD (n=25)		Low BMD (n=88)	
	Pearson correlation. r	p value	Pearson correlation. r	p value
PA	-0.059	0.781	0.332	0.002
IC	0.081	0.701	0.358	0.001

The BMD of the lumbar spine L2-L4 was measured by DXA using Prodigy machine (GE Lunar Corporation, Madison, WI, USA) by the same operator in the National Osteoporosis Center. Based on the bone densitometry findings, in accordance with the World Health Organization (WHO) classification, the subjects were classified as normal BMD (T-score > -1.0), and as having low BMD (T-score  $\leq$  -1.0) (14).

In order to assess the accuracy of the research findings, 30 % of the radiograms were examined additionally: twice by the person conducting the study and once by an independent investigator. The statistical analysis was performed using Statistical Package for the Social Sciences (SPSS; version 20.0; SPSS Inc., Chicago, IL). The following descriptive statistics are reported: means and standard deviations (SD). An independent samples Student's t-test was used to compare the mean of variables between independent groups and the paired Student's t-test was used to compare IC and PA at both sides of mandible. Receiver operating characteristics (ROC) curve analysis was used to determine the validity of cortical measurements in the diagnosis of low BMD obtained and the area under the ROC curve (AUC) was calculated. According to an arbitrary guideline, we distinguished between non-informative (AUC=0.5), less accurate (0.5<AUC<0.7), moderately accurate (0.7<AUC<0.9), highly accurate (0.9<AUC<1) and perfect tests (AUC=1) (21). The Pearson's correlation coefficient (r) was used for the analysis of the correlation between selected variables. All reported p-values are two tailed and results with p-values of < 0.05 were considered statistically significant.

## RESULTS

In this study, 130 women were examined (mean age 63.15 $\pm$ 6.05 years). Body Mass Index was calculated 26.1 $\pm$ 3.61. Further characteristics of the sample, such as T-score, BMD, PA, IC, the age when menopause began and years after menopause are shown in Table 1. High levels of intra- and interobserver agreement were demonstrated (respectively value of  $\kappa$  was 0.85 and 0.73). According to T-score values their status was defined as normal BMD in 22.1% (n=25), and as having low BMD in 77.9% (n=88). Correlations between PA and IC indices and BMD are shown in Table 2. The relationships between normal,

low BMD and PA, IC are demonstrated in Figure 1. In order to determine the validity of mandibular cortical measurements in the prognosis of low skeletal BMD receiver operating characteristics was used (Figure 2). Sensitivity indicates the probability that case is correctly identified (TP), and 1-specificity is the probability that normal subject is falsely identified as case. The areas under the ROC (AUC) of PA was 0.753 (95% CI, 0.645-0.861) and of IC was 0.709 (95% CI, 0.601-0.816).

## DISCUSSIONS

Osteopenia/low BMD which can lead to osteoporosis and is far more prevalent. Osteoporosis affects both bone quantity and quality with thinning of the cortical bone and cavity expansion due to bone absorption at the endosteum surface as well as reduced bone density. It leads to enhanced bone fragility and an increase in fracture risk. Early diagnosis of it is important in order to reduce fracture risk and to initiate early treatment. The first link between osteoporosis and bone loss in the oral cavity was established by Groen *et al.* in the 1960s (19). The jaw bone, despite its uniquely discrete location and function, remains part of the skeletal system and is metabolically regulated along with other aspects of the skeleton, including the vertebrae and long bones-sites frequently prone to osteoporotic fracture (1).

Various techniques have been used to assess BMD within the mandible, including DXA, quantitative computed tomography (QCT) and radiographic absorptiometry, as well as panoramic radiographs. QCT method is widely used in the lumbar vertebrae and femur for the diagnosis of OP, to the quantitative and objective assessment of jaw bone quality. The disadvantages of QCT method are relatively high exposure dose compared to that required for other radiography methods and its poor reproducibility due to high sensitivity to patient positioning (3). Panoramic radiographs are used extensively in dentistry and allow the study and evaluation of jaw bone structure. Identification of the signs of OP in dental panoramic radiographs is decisive in the diagnosis of this condition. That's why we choose panoramic radiography method for the cortical bone investigation.

This study demonstrated an association between the BMD, T-score and panoramic measurements within the total, normal and low BMD groups. We found that skeletal low BMD could be suspected by the measurements of mandibular inferior cortex on panoramic radiographs. In panoramic radiographs a number of mandibular indices have been made to do

the quantitative measuring of the mandibular bone mass and trabecular architecture in order to diagnose patients with osteoporosis (3-6, 16, 17, 20, 22-25). The importance of panoramic radiographs identifying low skeletal BMD in postmenopausal women was demonstrated by Taguchi *et al.* (23). They suggested that higher percentage of postmenopausal women with osteopenia and osteoporosis as well as spinal fractures may be identified based on trained general dental practitioners's analyses of their panoramic radiographs. In our present study the area under the ROC curve (AUC) for identifying postmenopausal women with low BMD by PA was 0.753 (95% CI, 0.645- 0.861), and by IC was 0.709 (95% CI, 0.601-0.816), which was classified as moderately accurate. This implies that postmenopausal women with spinal low BMD can be identified moderately accurately by PA and IC. The comparable results were demonstrated by Devlin and Horner in 74 Caucasian women aged 43-79 years (mean age 62 yrs) (22). They reported that the AUC for identifying postmenopausal women with low skeletal BMD by mandible cortical width was 0.733 (95% CI, 0.618-0.830). The objective of Marandi *et al.* was to evaluate the diagnostic efficacy of panoramic-based indices of the mandible (Mental Index, Mandibular Cortical Index and Panoramic Mandibular Index) and to determine their correlation with BMD of the femoral neck and lumbar vertebrae (L2-L4) in order to assess the possibility of using these parameters as indicators of OP (25). They state that radiomorphometric indices of the mandible may be useful in determining the skeletal status of the patients, but is not sufficient for precise evaluation. More recently, Bhatnagar *et al.* sought to evaluate panoramic radiograph as a screening tool to detect early osseous changes of the mandibular inferior cortex and measure the mandibular cortical width in postmenopausal women (4). They concluded that the combined mandibular cortical findings ( $p < 0.05$ ) and mandibular cortical shape erosion alone ( $p < 0.001$ ) on panoramic radiograph are effective indicators of osteoporosis in postmenopausal women. The BMD was measured by the ultrasound bone sonometer at the mid-shaft tibia region. Ishi *et al.* evaluated whether alveolar bone loss (ABL) of the mandible on panoramic radiographs is useful for identifying femoral osteoporosis (20). They found that ABL of the mandible on panoramic radiographs may not be useful for identifying postmenopausal women with femoral OP in comparison with mandibular cortical width.

In the studies of the influences of menopause on all the bones of the body, the evident loss of bone mass and BMD after menopause have been reported

for lumbar vertebral bodies and the femur. Taguchi *et al.* revealed that postmenopausal women with a thinner or eroded cortex of the mandible detected on dental panoramic radiographs had an increased risk of low vertebral BMD or osteoporosis (24). The rapid decrease in both the skeletal BMD and mandible cortical bone increases especially in the 5-10 year period after menopause. Our results suggest that there is statistical significant correlation between mandibular cortical width and spinal low BMD in postmenopausal women. The mean age at which menopause occurred was 50. Munakata *et al.* suppose that in the postmenopausal women there is no correlation between BMD and trabecular bone region width and cortical width (3). The question is what was the average of the age in the postmenopausal participants in their study? It is difficult to compare 63.15±6.05 years with wide range from 40 to 78 years. Perhaps the results may be affected by a small group of our subjects with normal BMD (n=25) and different investigative methodology. We used panoramic radiographs method which is wide used in dental practice while Munakata *et al.* used QCT method.

Furthermore, the jaw bone can be affected by the loss of posterior teeth resulting in the loss of neuromuscular stability of the mandible and reduced masticatory efficiency. Therefore, in the mandible where teeth are lost, the bone density may be reduced and the loss of trabecular bone density as well as cortical bone resorption from the inside can advance with menopause just as they do in bones in other parts of the body (3). Studies regarding the influence of dentition status to the mandible cortical width are controversial. Dutra and Gulsahi have reported, dentition status may influence the mandibular cortical width (16, 17). However Bollen *et al.* suggest that a history of osteoporotic fractures is not an important cause for tooth loss and residual ridge resorption in an elderly population (26).

Our study has some limitations. First, we did not evaluate the dentition status and occlusal function of the participants. The possibility exists that occlusal function influences the association between the mandibular cortical width and spine BMD. Adjusting for occlusal function might influence the results. The second limitation is the small sample size with normal BMD. Further study, including more participants with normal BMD and taking into consideration the number of residual teeth, is necessary to clarify our results. It should be taking into account that most of the elderly have more opportunities to visit a dental clinic for the treatment of dental caries or periodontal disease than to visit a medical clinic for the diagnosis of osteoporosis prior to fractures, a large proportion of postmenopausal women depend to the high-risk groups to remain undiagnosed from osteoporosis (20). Early identification of women at increased risk of fracture because of osteoporosis presents an opportunity for intervention to decrease fracture risk. In conclusion, the diagnostic efficacy of the mandible cortical measurements in identifying low BMD was moderately accurate. Panoramic radiography gives sufficient information to make an early diagnosis regarding low BMD in postmenopausal women. Our results suggest that undetected low spine BMD can be suspected in postmenopausal women by using radiomorphometric measurements in order to refer them to medical professionals for further investigation.

## CONCLUSION

According to the study on the basis of it can be concluded that the panoramic radiographic changes of mandible appear to be associated with low BMD. Postmenopausal women with spinal low BMD can be identified moderately accurately by mandibular cortical findings.

## REFERENCES

1. Takaishi Y, Arita S, Honda M, Sugishita T, Kamada A, Ikeo T, Miki T, Fujita T. Assessment of Alveolar Bone Mineral Density as a Predictor of Lumbar Fracture Probability. *Adv Ther* 2013; 30:487–502.
2. Osteoporosis Prevention, Diagnosis, and Therapy. NIH Consensus Statement 2000; March 27-29;17(1):1-36.
3. Munakata M, Tachikawa N, Honda E, Shiota M, Kasugai S. Influence of menopause on mandibular bone quantity and quality in Japanese women receiving dental implants. *Arch Osteoporos* 2011;6:51–57.
4. Bhatnagar S, Krishnamurthy V, Pagare SS. Diagnostic Efficacy of Panoramic Radiography in Detection of Osteoporosis in Post-Menopausal Women with Low Bone Mineral Density. *J Clin Imaging Sci* 2013;3:23.
5. Balcikonyte E, Balciuniene I, Alekna V. Panoramic Radiographs in Assessment of the Bone Mineral Density. *Stomatologija* 2004;6:17-19.
6. Miliuniene E, Alekna V, Peculiene V, Tamulaitiene M, Maneliene R. Relationship between mandibular cortical bone height and bone mineral density of lumbar spine. *Stomatologija* 2008;10:72-75.
7. Nackaerts O, Jacobs R, Horner K, Zhao F, Lindh C, Karayianni K, van der Stelt P, Pavitt S, Devlin H. Bone density measurements in intra-oral radiographs. *Clin Oral Investig* 2007;11:225–229.
8. Drage N, Palmer R, Blake G, Wilson R, Crane F, Fogelman I. A comparison of bonemineral density in the spine, hip and jaws of edentulous subjects. *Clin Oral Implants Res*

- 2007;18:496–500.
9. Bonakdar ZS, Karimzadeh H, Karimifar M, Mottaghi P, Salesi M, Farajzadegan Z. Definition of a population-specific dual energy X-ray absorptiometry reference standard in Isfahani women. *Int J Rheum Dis* 2008;11:400–406.
  10. Kavitha MS, Asano A, Taguchi A, Kurita T, Sanada M. Diagnosis of osteoporosis from dental panoramic radiographs using the support vector machine method in a computer-aided system. *Medical Imaging* 2012;12:1.
  11. Povorožnik VV, Mazur I P. *Kostnaja sistema i zaboljevanija parodontita*. Kiev;2003.
  12. Drazdzowska B, Pluskiewicz W, Tarnawska B. Panoramic-based mandibular indices in relation to mandibular bone mineral density and skeletal status assessed by dual energy X-ray absorptiometry and quantitative ultrasound. *Dentomaxillofac Radiol* 2002;31:361–67.
  13. Ledgerton D, Horner K, Devlin H, et al. Radiomorphometric indices of the mandible in a British female population. *Dentomaxillofac Radiol* 1999;28:173–81.
  14. World Health Organization. Assessment of Fracture Risk and its Application to Screening for Postmenopausal Osteoporosis. *World Health Organ Tech Rep Ser* 1994;843:1–129.
  15. Taguchi A. Triage screening for osteoporosis in dental clinics using panoramic radiographs. *Oral Dis* 2010;16:316–327.
  16. Dutra V, Yang J, Devlin H, Susin C. Radiomorphometric indices and their relation to gender, age, and dental status. *Oral Surg Oral Med Oral Pathol Oral Radiol Endod* 2005;99:479–484.
  17. Gulsahi A, Yu zu gu llu B, Imirzalioglu P, Genc, Y. Assessment of panoramic radiomorphometric indices in Turkish patients of different age groups, gender and dental status. *Dentomaxillofac Radiol* 2008;37:288–292.
  18. Taguchi A, Sugino N, Miki M, Kozai Y, Mochizuki N, Osanai H, Yamada S, Kuroiwa H, Fujiki H, Uchida K, Yoshinari N, Kashima I. Detecting young Japanese adults with undetected low skeletal bone density using panoramic radiographs. *Dentomaxillofac Radiol* 2011;40:154–159.
  19. Groen JJ, Duyvensz F, Halsted JA. Diffuse alveolar atrophy of the jaw (non-inflammatory form of paradental disease) and pre-senile osteoporosis. *Gerontol Clin* 1960;2:68–86.
  20. Ishii K, Taguchi A, Nakamoto T, Ohtsuka M, Sutthiprapaporn P, Tsuda M, Kodama I, Kudo Y, Sumida H, Suei Y and Tanimoto K. Diagnostic efficacy of alveolar bone loss of the mandible for identifying postmenopausal women with femoral osteoporosis. *Dentomaxillofac Radiol* 2007;36:28–33.
  21. Swets JA. Measuring the accuracy of diagnostic systems. *Science* 1988; 240:1285–1293.
  22. Devlin H, Horner K. Mandibular radiomorphometric indices in the diagnosis of reduced skeletal bone mineral density. *Osteoporos Int* 2002;13:373–378.
  23. Taguchi A, Ohtsuka M, Nakamoto T, Naito K, Tsuda M, Kudo Y, Motoyama E, Suei Y, Tanimoto K. Identification of post-menopausal women at risk of osteoporosis by trained general dental practitioners using panoramic radiographs. *Dentomaxillofac Radiol* 2007;36:149–154.
  24. Taguchi A, Ohtsuka M, Tsuda M, Nakamoto T, Kodama I, Inagaki K, Noguchi T, Kudo Y, Suei Y, Tanimoto K. Risk of vertebral osteoporosis in post-menopausal women with alterations of the mandible. *Dentomaxillofac Radiol* 2007;36:143–148.
  25. Marandi S, Bagherpour A, Imanimoghaddam M, Hatef MR, Haghighi AR. Panoramic-Based Mandibular Indices and Bone Mineral Density of Femoral Neck and Lumbar Vertebrae in Women. *J Dent* 2010;7:98–106.
  26. Bollen AM, Taguchi A, Hujoel PP, Hollender LG. Number of teeth and residual alveolar ridge height in subjects with a history of self-reported osteoporotic fractures. *Osteoporos Int* 2004;15:970–974.

Received: 20 10 2015

Accepted for publishing: 26 09 2016