

Immediate post-treatment crowned Herbst effects in growing patients

Dalia Latkauskienė, Gundega Jakobsonsone

SUMMARY

Objective. The aim of this prospective study was to describe the mechanism of Class II correction in growing patients induced by crown Herbst (cHerbst) appliance as an immediate result of therapy.

Materials and methods. Forty patients (mean age 13.6 ± 1.3 years) with stable Class I occlusion 1 year following treatment with the cHerbst appliance were selected from a prospective sample of 180 consecutively treated Class II patients. No other appliances were used during treatment. The immediate dentoskeletal changes after discontinuing cHerbst therapy were compared with a matched sample of untreated Class II subjects (mean age 13.9 ± 1.6 years). Lateral cephalograms were taken before treatment and immediately after one year therapy.

Results. Treatment produced significant skeletal changes: increase in mandibular length and SNB angle, decrease of ANB angle, restricted growth of posterior maxilla. Significant dentoalveolar changes: maxillary molars moved backwards and tipped distally, lower first molars moved forward and extruded, lower incisors proclined, upper incisors retroclined, overjet and overbite decreased.

Conclusions. Immediate posttreatment results revealed that Class II was mainly corrected due to dentoalveolar changes and only limited skeletal change.

Key words: Class II malocclusion, crown Herbst appliance.

INTRODUCTION

Herbst appliance was proved to be effective for correcting Class II malocclusion (1, 2). Stainless steel crown Herbst (cHerbst) was introduced by Langford in 1980 (3). Only a few studies on cHerbst are available in the literature (4, 5, 6). Those studies reported the results after the fixed appliance therapy conducted immediately after the cHerbst, so the pure cHerbst effects were not revealed (5, 6). Recent systemized review by Barnett et al (4) stated that still there had been not enough information of good quality to evaluate immediate changes after the banded Herbst or cHerbst appliance therapy.

METHODS

Inclusion criteria: at least end-to-end Class II molar relationship bilaterally or more severe, permanent

¹*Clinic of Orthodontics, Faculty of Odontology, Medical Academy, Lithuanian University of Health Sciences, Kaunas, Lithuania*

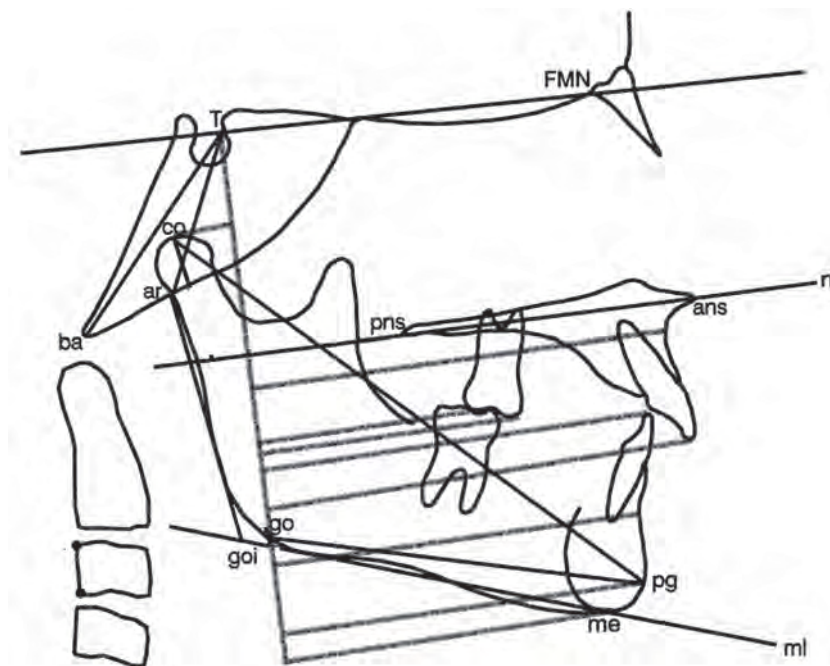
²*Department of orthodontics, Institute of Stomatology, Riga Stradins University, Riga, Latvia*

*Dalia Latkauskienė*¹ – PhD student
*Gundega Jakobsonsone*² – D.D.S., Dr. med. sc.

Address correspondence to: Dalia Latkauskienė, J.Lukšos-Daumanto g. 6, LT 50106 Kaunas.
E-mail address: dalia.lat@gmail.com

dentition, no previous orthodontic treatment or tooth extractions, fair oral hygiene, no periodontal problems, no temporomandibular joint complaints and lesions, no tooth size, form and number anomalies, no syndroms. Initial records: dental casts, panoramic x-ray, lateral cephalogram. Prior to cHerbst all Class II division 2 patients received braces on the upper front teeth to convert the malocclusion into Class II division 1, for those patients the first diagnostic lateral cephalogram was performed after alignment.

One hundred eighty included patients were treated by the same orthodontist (D. L.). CHerbst (Ormco, 1717 West Collins Avenue, Orange, CA) was used as the only tool for 12 months. Management was described previously (7). All the patients who finished treatment were treated to Class I occlusion, lateral cephalogram was performed on the appliance removal day. Patients were followed for 12 months with no other appliance to retain the occlusion. In case of relapse to Class II, patients were removed from the further study. Patient flow chart was described earlier (7). One year after treatment 65 patients presented with Class I occlusions. Study group: 40 stable patients (20 male, 20 female, mean age 13.6 ± 1.3 years) who were considered as growing during the active treatment phase. The Cervical Vertebral Maturation (CVM)



Abreviation	Explanation
FMN	Frontomaxillary nasal suture
T	The most superior point of the anterior wall of sella turcica, at the junction with tuberculum sellae
Co	Condylion. The most superior midline point on the condyle of the mandible.
Go	Gonion. A point on the curvature of the angle of the mandible located by bisecting the angle formed by lines tangent to the posterior ramus and the inferior border of the mandible.
Pg	Pogonion. The most anterior point of the chin.
Me	Mention. The lowest point of the sympheseal shadow of the mandible seen on a lateral cephalogram.
Gn	Gnathion. A point located by taking the midpoint between pogonion and mention.
S	Sella. The geometric centre of the pituitary fossa.
N	Nasion. The most anterior point of the frontonasal suture in the midsagittal plane.
A	Subspinale. The most posterior midline point in the concavity between the ans and the most inferior point on the alveolar bone overlying the maxillary incisors.
B	Supramentale. The most posterior midline point in the concavity of the mandible between the most superior point on the alveolar bone overlying the mandibular incisors and pg.
Ans	Anterior nasal spine. The anterior tip of the sharp bony process of the maxilla at the lower margin of the anterior nasal opening.
Pns	Posterior nasal spine. The posterior spine of the palatal bone constituting the hard palate.

Figure. A modified Pancherz cephalometric analysis

method (8) was used on pre-treatment and post-treatment lateral cephalograms to evaluate their skeletal maturity.

Control group: 18 subjects (11 males, 7 females, mean age 13.9 ± 1.6 years) selected from the longitudinal records of the University of Michigan and the Denver Growth Studies and matched to the treated group as to skeletal maturity before and after treatment.

Cephalometric analysis

Cephalograms were taken with the Frankfurt horizontal parallel to the floor with teeth in occlusion and lips relaxed. All cephalograms were hand traced and digitized by G. J. with Dentofacial Planner Plus software (Dentofacial Software, Toronto, Canada) on a computer with a digitizing screen (Numonics Cooperation, Montgomeryville, USA). All cephalograms were adjusted to 0% enlargement.

Frontomaxillary nasal suture (FMN) and T point were used to construct the reference lines as suggested by Franchi et al. (9). The following landmarks were digitized (Figure): condylion (co), gonion (go), A point, B point, pogonion (pg), menton (me), upper first molar mesiobuccal cusp tip (ms), lower first molar mesiobuccal cusp tip (mi), upper incisor tip (is), lower incisor tip (ii). Linear and angular measurements were performed: overbite, mandibular length (co-gn), maxillary unit length (co-A), ramus length (co-go), mandibular body length (go-me), SNA, SNB, ANB, SNpg, co-go-me, upper incisor inclination to T-FMN line, lower incisor inclination to mandibular plane (ml), upper molar axial line (mesiobuccal cusp to mesiobuccal root) inclination – to T-FMN line (upper molar tipping), maxillary plane to T-FMN line, mandibular plane to T-FMN line.

Statistical analysis

Statistical analysis was performed with SPSS for Windows software (SPSS, Chicago, IL). Shapiro-Wilk, Levene and independent t-tests tests were used. The power of the study was calculated considering the ANB angle. With a clinically significant change of 2.0 degrees in the ANB, a SD for this angle of 1.3 degrees (as derived from a previous study on the effects of the stainless steel crown Herbst), and alpha of 0.05, the calculated power for the independent sample t test exceeded 0.90.

Method error

Twenty cephalograms selected randomly from the treated sample were re-examined by G. J. on 2 separate occasions at least two weeks apart to calculate method error with Dahlberg's formula (10) and to assess the

intraclass correlation coefficient (ICC). Method error for linear measurement ranged from 0.3 mm (lower incisor to T-FMN line) to 0.7 mm (lower mandibular cusp to T-FMN line) and for angular measurements – 0.2 degrees for ANB angle to 1.2 degrees for lower incisor inclination. ICC for linear measurements varied from 0.949 for overjet to 0.998 for Point B to the Y – axis. For angular measurements, the values ranged from 0.962 (for maxillary plane to T-FMN line) to 0.988 (for SNA and SNB angles).

RESULTS

Differences between the treated and control samples prior to treatment presented in Table 1. The immediate dental and skeletal changes are presented in Table 2.

Skeletal changes

The cHerbst appliance had no effect on the sagittal position of the maxilla. Total mandibular length (co-gn) showed a statistically significant increase. CHerbst treatment resulted in following significant findings: increased SNB angle, decreased ANB angle, restriction of posterior maxilla (nl to T-FMN).

Dental changes

Significant changes: reduced overjet and overbite, upper first molars moved backwards and tipped distally, upper incisors retruded, lower first molars moved forward and extruded, lower incisors proclined significantly.

DISCUSSION

Skeletal changes

The increase in mandibular length induced by cHerbst therapy was found to be similar to that reported

Table 1. Pretreatment characteristics of the study subjects compared with matched untreated Class II individuals. Mean values and standard deviations (SD) in parenthesis

Variable	Study Group n=40	Control Group n=18	P value
Overjet (mm)	5.5 (2.2)	5.5 (2.4)	0.130
Overbite (mm)	5.6 (1.3)	4.5 (2.0)	0.758
SNA (degrees)	81.5 (2.9)	81.1 (3.8)	0.605
SNB (degrees)	76.7 (2.4)	76.6 (3.2)	0.910
SNpg (degrees)	78.1(2.6)	78.0 (3.3)	0.886
ANB (degrees)	4.8 (1.9)	4.5 (1.5)	0.449
co-A (mm)	86.6 (4.7)	83.6 (6.6)	0.045
co-gn (mm)	108.1 (5.4)	105.8 (7.3)	0.187
is to T-FMN (degrees)	111.5 (8.2)	104.4 (8.2)	0.003
ii to ml (degrees)	99.8 (7.0)	98.7 (7.6)	0.599
co-go-me (degrees)	121.5 (4.9)	119.8 (4.1)	0.178

in some other studies (5, 6, 11). Because previous studies on the factors influencing relapse after Herbst treatment (13, 14) stressed the importance of stable occlusion at the end of Herbst therapy, our treatment objective was to establish Class I relationship during the active phase of treatment: cHerbst was re-activated to achieve maximum intercuspation in Class I (7) instead of edge-to-edge re-activation recommended by Pancherz (12).

In agreement with Pancherz (12) but in contrast with Valant et al (11) no inhibition of maxillary growth was detected in our study.

Table 2. Comparison of the changes in the variables immediately after cHerbst treatment. Mean values and standard deviations (SD) in parenthesis

Variable	Study Group	Control Group	P value
Skeletal measurements			
co hor	-0.9 (1.2)	-0.4 (1.3)	0.198
co ver	0.3 (1.2)	0.9 (1.3)	0.098
A hor	0.5 (1.0)	0.9 (1.2)	0.161
B hor	1.7 (1.9)	1.0 (1.7)	0.185
pg hor	1.9 (2.1)	1.4 (2.1)	0.383
me ver	3.4 (1.6)	2.6 (2.7)	0.193
co-A	1.6 (1.5)	1.3 (1.8)	0.593
co-gn	4.0 (1.8)	2.7 (2.4)	0.026
co-go	2.7 (3.7)	1.1 (1.5)	0.071
go-me	1.4 (3.1)	1.3 (2.7)	0.913
SNA	-0.3 (0.9)	0.2 (1.1)	0.142
SNB	0.8 (1.0)	0.1 (0.8)	0.014
SNpg	0.7 (0.9)	0.3 (0.6)	0.122
ANB	-1.1 (1.0)	0.0 (0.7)	0.000
nl to T-FMN	0.7 (1.2)	-0.5 (1.9)	0.005
ml to T-FMN	0.3 (1.9)	0.1 (2.0)	0.684
co-go-me	0.6 (2.8)	0.7 (1.7)	0.890
Dental measurements			
Overjet	-2.7 (1.9)	0.0 (0.8)	0.000
Overbite	-2.7 (1.3)	-0.4 (0.7)	0.000
ms hor	-1.6 (1.6)	1.1 (1.7)	0.000
ms ver	1.4 (1.2)	1.7 (1.9)	0.501
Upper molar tipping	-5.7 (4.5)	1.4 (4.1)	0.000
mi hor	3.6 (1.9)	1.1 (1.7)	0.000
mi ver	2.6 (1.3)	1.6 (2.0)	0.031
is hor	0.1 (1.8)	1.0 (1.3)	0.076
is ver	1.6 (1.4)	1.1 (1.6)	0.291
ii hor	2.9 (1.7)	1.0 (1.6)	0.000
ii ver	4.3 (1.7)	1.5 (2.0)	0.000
Upper incisor inclination	-2.3 (4.6)	0.3 (2.1)	0.023
Lower incisor inclination	4.6 (4.1)	-0.8 (3.4)	0.000

In agreement with Valant et al. (11) in contrast with Pancherz and Fackel (15) we couldn't verify the increase in facial height after the Herbst therapy (co-go-me, ml to T-FMN)

Dental changes

Immediately after cHerbst therapy upper incisors showed tendency to upright, in agreement with Pancherz (12) and Valant (11) findings.

Lower incisors were significantly proclined by 4.6 degrees in our study. In Weschler et al (16) study lower incisors proclined by 9.4 degrees independently of the anchorage form used in the mandible (cast splint compared to banded anchorage forms). The explanation might be the cHerbst activation procedure we followed. Edge to edge appliance activation (16) might create greater forces in the mandibular front segment and cause more proclination comparing to gradual activation process. However this was not supported by Du Xi et al (17).

In agreement with Valant et al (11) upper first molars were significantly distalized, though on no intrusion was detected, probably due to the absence of acrylic layer on the lower arch. The maxillary first molar distal

movement detected by Pancherz (12) was greater than in our and Valant et al. (11) study, although in Pancherz appliance design (12) upper first molars were connected with the first premolars both sides to increase anchorage. Greater anchorage loss for upper molars in Pancherz study might also be the outcome of either excessive appliance activation or severity of malocclusion at the start of treatment.

Lower first molars moved significantly forward by 3.6 mm in agreement with Pancherz (12) findings (4.4 mm). Greater anchorage loss in Pancherz (12) study could be attributed to severity of malocclusion.

CONCLUSIONS

- CHerbst therapy increased mandibular length significantly immediately after treatment;
- Appliance restricted vertical growth in posterior maxilla;
- Substantial distalization of the upper molars was achieved without significant effect on the upper incisors;
- Class II was mainly corrected due to dentoalveolar changes.

REFERENCES

1. Cozza P, Baccetti T, Franchi L, De Toffol L, McNamara JA. Mandibular changes produced by functional appliances in Class II malocclusion: a systematic review. *Am J Orthod Dentofacial Orthop* 2006;129:e599
2. Aelbers CMF, Dermaut LR. Orthopedics in orthodontics: Part I, fiction or reality: a review of the literature. *Am J Orthod Dentofacial Orthop* 1996;110:513-9.
3. Langford NM, Jr. The Herbst appliance. *J Clin Orthod* 1980;15:58-61.
4. Barnett G, Higgins D, Major P, Flores-Mir C. Immediate Skeletal and Dentoalveolar effects of the crown- or banded type Herbst appliance on Class II division I malocclusion. *Angle Orthod* 2008;78:361-9.
5. Burkhardt D, McNamara JA, Baccetti T. Maxillary molar distalization or mandibular enhancement: A cephalometric comparison of comprehensive orthodontic treatment including the pendulum and the Herbst appliances. *Am J Orthod Dentofacial Orthop* 2003;123:108-16.
6. Schaefer AT, McNamara JA Jr, Franchi L, Baccetti T. A cephalometric comparison of treatment with the twin-block and stainless steel crown Herbst appliances followed by fixed appliance therapy. *Am J Orthod Dentofacial Orthop* 2004;126:7-15.
7. Latkauskienė D, Jakobsone G, McNamara JA. A prospective study on the clinical effectiveness of the stainless steel crown Herbst appliance. *Progress in Orthod* 2012;13:100-8.
8. Baccetti T, Franchi L, McNamara JA Jr. The cervical vertebral maturation (cvm) method for the assesment of optimum treatment timing in dentofacial orthopedics. *Semin Orthod* 2005;11:119-29.
9. Franchi L, Baccetti T, McNamara JA Jr. Treatment and post treatment effects of acrylic splint Herbst appliance therapy. *Am J Orthod Dentofacial Orthop* 1999;115:429-38.
10. Dahlberg G. Statistical methods for medical and biological students. New York: Intersci. publ.; 1940.
11. Valant JR, Sinclair PM Treatment effects of the Herbst appliance *Am J Orthod Dentofacial Orthop* 1989;95:138-47.
12. Pancherz H. The mechanism of Class II correction in Herbst appliance treatment: a cephalometric investigation. *Am J Orthod* 1982;82:104-13.
13. Hansen K, Pancherz H, Hagg U. Long term effects of the Herbst appliance in relation to the treatment growth period: a cephalometric study. *Eur J Orthod* 1991;13:471-81.
14. Pancherz H. The nature of Class II relapse after Herbst appliance treatment: a cephalometric long term investigation. *Am J Orthod Dentofacial Orthop* 1991; 100:220-33.
15. Pancherz H, Fackel U. The skeletofacial growth pattern pre- and post-dentofacial orthopaedics. A long term study of Class II malocclusions treated with the Herbst appliance. *Eur J Orthod* 1990;12:209-18.
16. Weschler D, Pancherz H. Efficiency of three mandibular anchorage forms in Herbst treatment: a cephalometric investigation. *Angle Orthod* 2005;75:23-7.
17. Du Xi, Hagg U, Rabie B. Effects of headgear Herbst and mandibular step-by-step advancement versus conventional Herbst appliance and maximum jumping of the mandible. *Eur J Orthod* 2002; 24:167-74.

Received: 09 03 2011

Accepted for publishing: 21 09 2012