

Damage of Inferior Alveolar Nerve in Mandible Fracture Cases

Dainius Razukevicius

SUMMARY

The investigation was performed on 195 patients, who had fracture on mandibular angle zone. In control group pain thresholds of infraorbital nerve and inferior alveolar nerve did not differ significantly ($p > 0.05$). Consequently, lesion degree of inferior alveolar nerve and its functional recovery dynamics was estimated objectively according to pain threshold and lesion index of neural function, namely, by dividing the pain threshold of inferior alveolar nerve by the one of infraorbital nerve. Stump dislocation extent has influence on neural lesion: the more expressed dislocation, the higher likelihood of severe lesion of inferior alveolar nerve. It was identified three degrees of neural lesion in the case of mandibular angle fracture. When minor lesion of inferior alveolar nerve takes place (17.4%), sensation recovers in 21 days after stump reposition and fixation; moderate lesion of nerve (55.8%) has sensory recovery after 28 days, and in the case of severe lesion of nerve (26.6%) neural function does not recover even after 90 days.

Key words: inferior alveolar nerve damage, mandible fracture

INTRODUCTION

Facial injuries are one of the main issues in maxillofacial surgery. They amount from 3.2% up to 8% of all injuries [1]. 79.7% of all facial injuries fall to mandibular fractures [2]. From 18 to 30% of cases, lower jaw has fracture on angle zone [3, 8, 9]. 36% of injured people are 20-29 years old. By men the injury occurs 8 times more frequently than by women [4]. 74% of mandibular injuries occur due to violence at home.

When mandibular fracture occurs on angle zone, inferior alveolar nerve always is injured, and at its innervation point emerge sensation disorders (lower lips, chin, alveolar process). Patients feel on this area discomfort, paresthesia, sometimes even pain. This condition has negative influence on psycho-emotional status of person and reduces working capacity. Lesions of inferior alveolar nerve and vascular bundle have an influence on course of lower jaw healing [5,6]. For evaluation of neuro-functional condition there are used different methods. Some authors [7,8] while investigating post-traumatic and post-operational lesions of inferior alveolar nerve used sharp/blunt differentiation and two-point discrimination for sensory abnormalities. Other researchers [10,14] point that for evaluation of inferior alveolar nerve condition, thermal method is more precise than tactile method. Some investigators back intervention surveys [11]: special needle electrode is pricked below zygoma against lower jaw temporal joint 4-4.5 cm deep by foramen ovale. The other electrode is put by mental foramen. Then it is registered the time of stimulus spread. This method is recommended as an objective diagnostic method for examination of inferior alveolar nerve lesions and recovery dynamics. We suggest, that this method is appropriate not for every patient, because this is associated with additional injury by reexamining. It is proven by experiments that the mean speed of impulse spread through inferior alveolar nerve is 65 m/s with no differences depending on side [12].

Dainius Razukevicius - D.D.S., PhD student at Department of Maxillofacial Surgery, Kaunas Medical University.

Address correspondence to Dainius Razukevicius: Department of Maxillofacial Surgery, Kaunas Medical University, Eiveniu 2, Kaunas, Lithuania.

The objective of the study was to explore functional condition of inferior alveolar nerve by fractures of mandibular angle, to estimate degree of the fracture, and to investigate the dynamics of neuro-functional recovery.

MATERIAL AND METHODS

At the Department of Maxillofacial Surgery of Kaunas University of Medicine in 2001-2004 were treated 195 patients with mandibular angle fractures and miscellaneous lesions of inferior alveolar nerve. Control group consisted of 20 persons who never had facial or jaw injuries. The distribution of respondents by age and sex is shown in Table 1. Among patients prevailed men (88.7%), and 15-44 years old persons (74.5%).

The fractures of mandibular angle were divided into two groups: fractures with minimal dislocation and fractures with significant dislocation (Figure 1).

Lesion of inferior alveolar nerve was diagnosed by comparing the cutaneous sensation of pain to sharp needle prick at innervation point of injured side with the sensation of pain at innervation point of infraorbital nerve. When mandibular fracture was double and post-traumatic edema of soft tissues was present, the pain threshold of infraorbital nerve was measured in the side, where post-traumatic outcomes at infraorbital zone were minimal and there were any subcutaneous bruising and scrapes.

The lesion degree of inferior alveolar nerve and recovery dynamics was estimated according to pain threshold. For measurement of pain threshold it was used *Pulptester Pt 1* device, which generates electric impulses of negative polarity, responding the polarity of neural signals. Measurements were performed on face skin, at mental foramen projection. Before measurement, the skin was cleaned with 70° alcohol, and measuring was made on dry skin. Then it was calculated the lesion index of neural function by dividing pain thresholds of inferior alveolar nerve and infraorbital nerve. Measurements were performed 1-3 days before treatment and then 7, 14, 21, 28, 45, 60, and 90 days after stump reposition and fixation.

Statistical data analysis was executed using the program for Windows "Statistical Package for Social Sciences" (SPSS).

RESULTS AND DISCUSSION

The pain threshold of right side inferior alveolar nerve in control group was 47.2 ± 3.5 mA, left side – 47.4 ± 3.3 mA, right side infraorbital nerve 46.7 ± 3.1 mA, and left side – 46.9 ± 3.3 mA (Table 2). The pain threshold differences at innervation point of inferior alveolar nerve and infraorbital nerve in control group did not reach the statistical significance ($p > 0.05$). This means, that for patients, who have bilateral inferior alveolar nerve lesions, the pain threshold can be compared with the pain threshold of infraorbital nerve.

By examining sensation disorders on patients' skin at innervation zone of inferior alveolar nerve, hyperalgesia was identified by 34 patients (17.3%), and hypoalgesia – by 161 patients (82.4%). For 31 patient (15.8%) hyperalgesia was diagnosed with minimal stump dislocation (Table 3) and only for 3 patients (1.5%) with significant stump dislocation. When significant stump dislocation was present, hypoalgesia was identified by 146 patients (74.8%) and only for 15 patients (7.69%) was diagnosed hypoalgesia with minimal stump dislocation.

The pain threshold at fracture side before treatment depended on the type of cutaneous sensation disorder. By hyperalgesia, the pain threshold of inferior alveolar nerve at fracture side was statistically significantly ($p < 0.05$) lower comparing with the pain threshold of infraorbital nerve at opposite side (Table 4). Lesion indexes of neural function by those patients were less than 1.0, with mean value of 0.56 ± 0.28 . Such neural lesion was considered as minor.

Pain thresholds differences by patients with hypoalgesia were statistically significant: threshold of inferior alveolar nerve at fracture side was higher than threshold of infraorbital nerve ($p < 0.05$), though they significantly differed among patients of this group. One subgroup (109 patients) had lesion indexes of neural function at interval from 1.0 to 2.0 (with mean 1.25 ± 0.12), and these lesions were considered as moderate. Other subgroup (52 patients) had lesion indexes of neural function more than 2.0 (with

mean value of 2.10 ± 0.11) and these lesions were considered as severe.

After analysis of neural function recovery of inferior alveolar nerve it was established, that the dynamics of neural function recovery mainly depended upon degree of lesion severity. When neural lesion was minor, after treatment and stump reposition and fixation, pain threshold increased at fracture side (Figure 2). After 21 day, the mean of pain threshold did not differ significantly comparing with the one of infraorbital nerve. In case of moderate lesion (Figure 3), after 7 days was registered increase of pain threshold. Statistically significant difference of means lasted until 21 day after stump reposition and fixation. After 28 days the pain threshold of inferior alveolar nerve declined and did not differ significantly from the pain threshold of infraorbital nerve. By patients with severe lesion of inferior alveolar nerve the increase of pain threshold also was registered

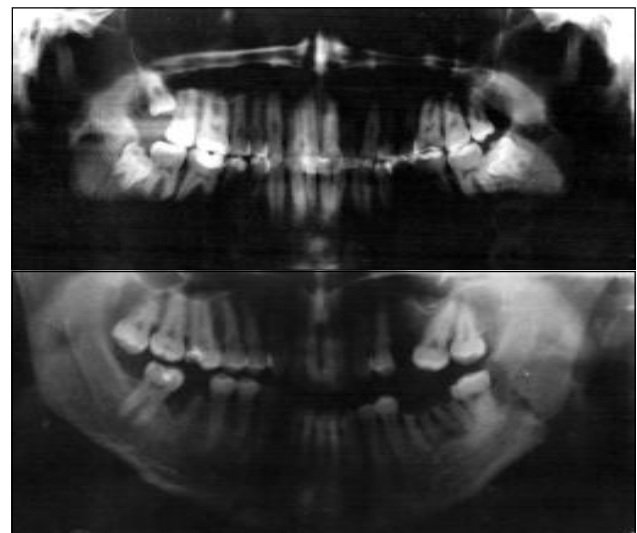


Figure 1. Dislocation of the fractured mandible.

Table 1. The distribution of respondents by sex and age.

| Study participants | Sex | | | | Age group | | | | | | | | Total |
|--------------------|------|------|--------|------|-----------|------|-------|------|-------|-----|-----|-----|-------|
| | Male | | Female | | 15–44 | | 45–59 | | 60–74 | | >74 | | |
| | n | % | n | % | n | % | n | % | n | % | n | % | |
| Patients | 173 | 88.7 | 22 | 11.3 | 145 | 74.5 | 32 | 16.4 | 17 | 8.7 | 1 | 0.5 | 195 |
| Control group | 14 | 70 | 6 | 30 | 15 | 75 | 5 | 25 | – | – | – | – | 20 |

Table 2. Pain threshold data of control group.

| Location of measurement | Pain threshold μ A | |
|--|------------------------|----------------|
| | Right side | Left side |
| Foramen mentale projection on skin | 47.2 ± 3.5 | 47.4 ± 3.3 |
| Foramen infraorbitale projection on skin | 46.7 ± 3.1 | 46.9 ± 3.3 |

Table 3. Relationship between sensation disorder and stump dislocation.

| Stump dislocation | Hyperalgesia | | Hypoalgesia | |
|-------------------|--------------|------|-------------|------|
| | n | % | n | % |
| Minimal | 31 | 15.8 | 15 | 7.69 |
| Significant | 3 | 1.5 | 146 | 74.8 |

Table 4. Pain threshold before stump fixation.

| Sensation disorder | Patients | Pain threshold | | Lesion index of neural function | Degree of lesion severity | Cases | |
|--------------------|----------|----------------|----------------|---------------------------------|---------------------------|------------|------|
| | | Intact side | Fracture side | | | n | % |
| Hyperalgesia | 34 | 47.2 ± 3.5 | 26.9 ± 2.1 | 0.56 ± 0.28 | minore | 34 | 17.4 |
| Hypoalgesia | 161 | 47.4 ± 3.3 | 59.5 ± 3.2 | 1.25 ± 0.12 | moderate | 109 | 55.8 |
| | | 47.3 ± 3.4 | 99.6 ± 5.5 | 2.10 ± 0.11 | severe | 52 | 26.6 |
| Total | | | | | | 195 | |

after 7 days (Figure 4), after 14 days pain threshold declined until 45 day. 90 days after stump fixation, pain threshold of inferior alveolar nerve statistically significantly was higher comparing with pain threshold of infraorbital nerve, and lesion index of neural function was 1.73 ± 0.12 .

By summarizing the results it can be stated, that the estimations of pain threshold of inferior alveolar nerve and setting of lesion index of neural function (comparing those thresholds at fracture side with the ones of infraorbital nerve), enables objectively evaluate the degree of lesion and functional recovery dynamics. It was set three lesion degrees of inferior alveolar nerve: minor, moderate, and severe. Every degree includes corresponding neural functional condition, which can be characterized by pain thresholds and lesion index of neural function. Besides, those three degrees differ by dynamics of neural function recovery and by outcomes.

Minor lesion of nerve shows sensation increase, which can be characterized by decline of pain threshold. Our results point that in this case the function of nerve recovers through time. Davis et al. [13], who investigated the reaction of peripheral nerves to injury, such condition of neural function called 'metabolic block', and the type of neural lesion – neurapraxia.

Moderate lesion of nerve is characterized by symptoms of neural function 'disappearance' (hypoalgesia), which points reversible structural changes, characterized by increase of pain threshold. Such condition of neural function is called 'demyelisation block', and the type – axonotmesis [13].

Severe lesion of nerve is characterized by lesion of axon integrity. Davis et al. call it neurotmesis.

What determines the degree of lesion of inferior alveolar nerve in case of fractures of mandibular angle? Our results show, that minor neural lesion occurs more frequently when minimal stump dislocation takes place (15.8%) rather than significant dislocation (1.5%).

Researchers are still discussing, how much influence on neural lesion has the stump dislocation. For instance, Shultze-Mosgau et al. [7] state, that by mandibular fractures when dislocation is more than 1 mm, sensory recovery is longer, and when dislocation is more than 5 mm, anesthesia or hypoesthesia lasts for more than 6 months.

CONCLUSIONS

In the case of mandibular angle fracture, the lesion of inferior alveolar nerve always takes place. This lesion can be minor, moderate or severe. The extent of stump dislocation has influence on this neural lesion: the more expressed dislocation, the higher likelihood of severe lesion of inferior alveolar nerve. The degree of lesion and recovery dynamics can be estimated by non-invasive and non-traumatic methods, i.e. by measuring pain threshold of inferior alveolar nerve and comparing it with corresponding infraorbital nerve data, and by estimating lesion index of neural function. The

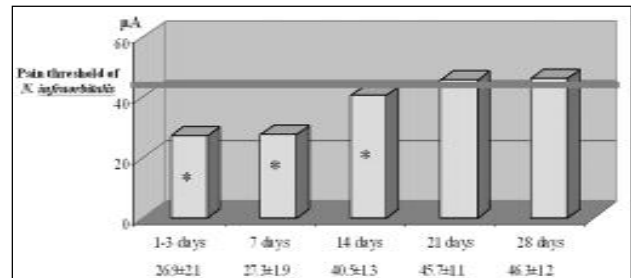


Figure 2. Dynamics of pain threshold of *N.alveolaris inferior*: minor lesion.
* statistically significant, comparing with pain threshold of *N.infraorbitalis*

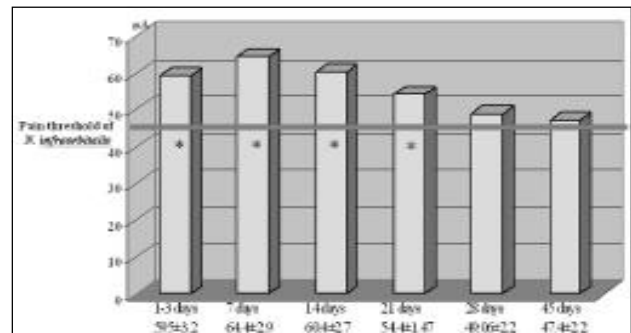


Figure 3. Dynamics of pain threshold of *N.alveolaris inferior*: moderate lesion.
* statistically significant, comparing with pain threshold of *N.infraorbitalis*

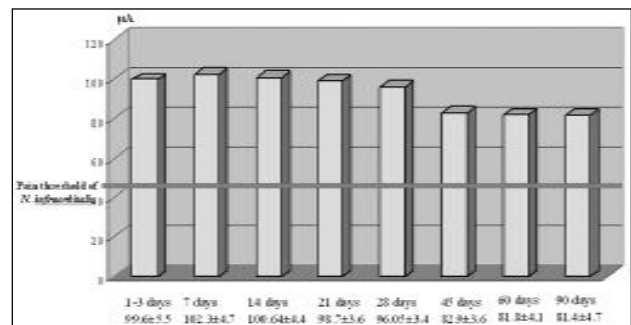


Figure 4. Dynamics of pain threshold of *N.alveolaris inferior*: severe lesion.
* statistically significant, comparing with pain threshold of *N.infraorbitalis*

recovery dynamics of neural function depends on lesion degree. After stump reposition and fixation, sensory recoveries take place: in case of minor lesion of nerve in 21 days, moderate lesion in 28 days. In severe lesion of inferior alveolar nerve, the function still does not recover even in 90 days after stump reposition and fixation.

REFERENCES

- Ellis E, Moos KF, el-Attar A. Ten years of mandibular fractures: an analysis of 2,137 cases. *Oral Surg Oral Med Oral Pathol* 1985; 59(2): 120-9.
- Бернадский ЮИ. Травматология и восстановительная хирургия челюстно-лицевой области. Киев; 1999.
- Hendler B. Maxillofacial Trauma. In: *Emergency Medicine: Concepts and Clinical Practice*. Rosen P, editor. Mosby-Year Book; 1998. p. 1093-103.
- Александров НМ, Аржанцев ПЗ, Вихриев БС. Травма челюстно-лицевой области. Под ред. Александра НМ, Аржанцева ПЗ. М.: Медицина; 1986. с. 7.
- Kubilius R. Apatinio alveolinio nervo neuropatija apatinio andikaulio lūžimū atvejais [Neuropathia of the lower alveolar nerve in cases of mandible fractures]. *Stomatologija* 2001; 3(1): 9-11. Lithuanian.
- Blaeser BF, August MA, Donoff RB, et al. Panoramic radiographic risk factors for inferior alveolar nerve injury after third molar extraction *J Oral Maxillofac Surg* 2003; 61(4): 417-21.
- Schultze-Mosgau S, Erbe M, Rudolph D, et al. Prospective study on post-traumatic and postoperative sensory disturbances of the inferior alveolar nerve and infraorbital nerve in mandibular and midfacial fractures *J Craniomaxillofac Surg* 1999; 27(2): 86-93.
- Campbell RL, Shamaskin RG, Harkins SW Assessment of recovery from injury to inferior alveolar and mental nerves. *Oral Surg Oral Med Oral Pathol* 1987; 64(5): 519-26.
- Cabrini Gabrielli MA, Real Gabrielli MF, Marcantonio E, Hochuli-Vieira E. Fixation of mandibular fractures with 2.0-mm miniplates: review of 191 cases. *J Oral Maxillofac Surg* 2003; 61(4): 430-6.

10. Van Sickels JE, Zysset M, Nishioka GJ, Thrash WJ : A comparative study of normal sensibility of the inferior alveolar nerve and the infraorbital nerve. *Oral Surg Oral Med Oral Pathol* 1989 ;67(3): 255-7.
11. Jaaskelainen SK. A new technique for recording sensory conduction velocity of the inferior alveolar nerve. *Muscle Nerve* 1999; 22(4): 455-9.
12. Colin WB. Conduction velocity of the human inferior alveolar nerve. Normative data. *Arch Otolaryngol Head Neck Surg* 1997; 123(2): 185-9.
13. Davis H. Mobilization of the alveolar nerve to allow placement of osseointegratable fixtures. In: *Advanced Osseointegration Surgery: Application in the Maxillofacial Region*. Quintessence Publishing Co Ltd; 2000. p. 129-41.
14. Blanas N, Kienle F, Sandor GK. Inferior alveolar nerve injury caused by thermoplastic gutta-percha overextension. *J Can Dent Assoc* 2004; 70(6): 384-7.

Received: 22 10 2004

Accepted for publishing: 20 12 2004