

Accuracy of Computerized Axiography Controlled by MRI in Detecting Internal Derangements of the TMJ

Giedre Kobs, Olaf Bernhardt, Georg Meyer

SUMMARY

Objectives: To evaluate the diagnostic accuracy of 3-D computed axiography to detect anterior disk displacements (ADD) of the temporomandibular joint (TMJ).

Methods: 564 joints with no disk displacement (NDD), 114 joints with reducible displaced disk (RDD) and 36 joints with permanently displaced disk (PDD) confirmed on magnetic resonance imaging (MRI) were examined by 3-D computerized axiography. The assessment of TMJ disk position was based on the sagittal MRI plane (the position of the disk was controlled by coronal images).

Results: Pathological TMJ states on axiography could be demarcated with sensitivity of approximately 80% and specificity of approximately 90% from healthy joints.

Conclusion: Within the limitations of this study we suggest, that jaw-tracking devices remains an accurate evaluation method for determination of TMJ dysfunction.

Keywords: temporomandibular disorders; craniomandibular disorders; internal derangement; computerized axiography; magnetic resonance imaging; sensitivity; specificity

INTRODUCTION

The most common temporomandibular joint disturbance is the internal derangement (ID). The prevalence has been shown to be as high as 28% [1]. According to Dolwick [2] the ID of TMJ may be defined as an abnormal anatomic relationship between the articular disk, mandibular condyle, fossa and articular eminence as well as changes in their form and structure. RDDs and PDDs are the two major forms of TMJ internal derangements. Non-invasive diagnostic methods are of great importance in assessment of the magnitude of these disturbances. MR imaging has become the gold standard for evaluating the soft tissue structures of the temporomandibular disorders (TMD), especially disk position [3], and it has the major advantage of not introducing radiation or known biologic hazards to the patient that might produce tissue damage [4]. The disadvantages of MR imaging are similar to those of CT scanning. MR imaging units are quite expensive and not available in a traditional dental setting. Computed axiography allows non-invasive three-dimensional imaging of the condylar path on the basis of recorded hinge-axis movements [5]. Axiographic recordings of the mandibular joint motion permit the diagnosis of muscular dyscoordination, hyper- and hypomobility, dynamic asymmetries of movement, avoidance mechanisms, and joint pathologies [6] and therewith improve the accuracy of clinical diagnosis. The experienced dentist is able to detect early symptoms of disturbances, which cannot be diagnosed us-

ing invasive methods. However, the literature does not suggest that the sensitivity and specificity of jaw-tracking devices are reliable enough to be used for diagnosis and management of TMDs [4, 7-9]. The objective of this study was to evaluate the diagnostic accuracy of 3-D computerized axiography to detect different stages of internal derangement of the temporomandibular joint (TMJ).

MATERIALS AND METHODS

From a population representative cross-sectional study - "Study of Health in Pomerania" (SHIP) there were 307 subjects (140 males and 167 females) selected for this investigation. The age of subjects ranged from 20 to 54 years old, with a mean age of 35, 4.

Due to the clinical diagnosis of „SHIP“ 114 subjects had at least one sign of temporomandibular disorders (tenderness/pain on palpation of the joints or muscles, TMJ sounds, pain or deviation during maximum mouth opening (active/passive). 193 subjects served as controls. In this investigation we did subgroup analysis and for the calculation of sensitivity and specificity do not rebuild the patient and control groups. Standardization and calibration of clinicians was performed before the study started and took place twice a year while the study was running. Kappa values for detecting palpation pain of the masticatory muscles and TMJ varied from 0.53 to 0.63 in the final calibration session. All subjects underwent computerized axiography and MRI after proper history taking and assessment of clinical symptoms. The involvement criterion for the response into this study was the participation in all three investigations.

The axiographic and MRI results were independently assessed by two experienced diagnosticians. The examiner had no knowledge of the clinical and MRI findings.

Collected data were compared by contingency tables and analysed with chi-square (χ^2) test. Better visualisation of results was done by graphics.

Giedre Kobs - D.D.S., PhD, Institute of Stomatology, Faculty of Medicine, Vilnius University, Lithuania.

Olaf Bernhardt - D.D.S., PhD, Ass.Prof., assistant medical director at the Department of Restorative Dentistry, Periodontology and Pediatric Dentistry, University of Greifswald, Germany.

Georg Meyer - D.D.D., PhD, Hab.Dr., Professor and Head of Department of Restorative Dentistry, Periodontology and Pediatric Dentistry, University of Greifswald, Germany.

Address correspondence to Dr.G.Kobs, Department of Prosthodontics, Institute of Stomatology, Faculty of Medicine, Vilnius University, Zalgirio str. 115, 2042 Vilnius, Lithuania.

MRI diagnosis

MRI was performed with 1,0-tesla scanner (Magnetom Impact Expert, Siemens, Germany) using a bilateral TMJ surface coil with 7cm diameter. The imagines were performed with the following Spin-Echo-Sequent Parameters:

- axial (Scout – image) - T1 weighted images, TR = 140, TE = 15, Flip 90
- sagittal – T1 weighted images. Nine images with 3mm slice thickness; TR = 448 ms, TE = 15, Flip = 90, Matrix% 75 (192*256)
- coronal - T1 weighted images, TR = 450, TE = 15, Flip = 90, Matrix% 75 (192*256)

Three (lateral, central und medial), 3 mm orthogonal sagittal images of the TMJ were obtained with the jaw in the maximal intercuspal position (MIP) and then at maximal opening. The position of the articular disk was determined in both cases, when the mouth was closed and when it was



Figure 1. Computerized axiography adjusted to head of patient.

open. The physiological disk position and disk displacement was defined as described previously [10].

After assessment of the disk position on the sagittal plane following diagnoses were made:

- No disk displacement (NDD)
- Partially disk displacement with complete reposition (part. DDCR)
- Partially disk displacement with partially reposition (part. DDPR)
- Complete disk displacement with complete reposition (compl. DDCR)
- Complete disk displacement with partially reposition (compl. DDPR)
- Complete disk displacement without reposition (compl. DDWR)
- Struck disk

Axiographic diagnosis

The registration of TMJ tracings was made with the conventional double face-bow Cadiax III-System (Gamma, Wien). Three-dimensionally adjustable lower bow is used to transmit hinge-axis movement of the mandible to the upper face bow (Fig 1).

In all cases the axiographic findings were recorded and assessed for both joints. The diagnoses were made on the basis of the following findings:

- no appreciable disease (NAD)
- disk displacement with early reposition (DDER)
- disk displacement with late reposition (DDLR)
- disk displacement without reposition (DDWR)
- not classifiable pathological change (NCPC)

RESULTS

The results of axiography in correlation to MRT findings on sagittal plane are compared in Fig. 2.

From Figure 2 it appears, that axiographic findings NAD over 90% were accurately recognised in both joints as having NDD on MRT. DDER was recognised over 70%, DDWR approximately 60% and DDLR 100% (n=6) of the cases (in both joints). If we summarise axiographic diagnosis DDER and DDLR (independently from reposition time), and confront with MRT findings part. DDCR, so 75, 0% of the cases (n=52) on the right side and 71, 2% of the cases (n=52) on the left side were diagnosed correctly. Axiographic findings NCPC had no disk displacement to 60% on the right joint and to 45% on the left joint.

For the calculation of the axiographic sensitivity and specificity, all axiographic diagnoses with appreciable disease were summarised and confronted with all kind of disk dislocations, diagnosed on MRT sagittal plane (Figure 3: a) left). For the right side sensitivity was 79, 2% and specificity 85, 1%. For the left side sensitivity was 74, 4% and specificity 86, 5%. The positive predictive value for the right joint was 62, 0% and for the left joint 65, 2%.

The results of this study showed, that on MRI diagnosed „stuck disk“ 90% had appreciable axiographic disease on the accordingly side (c²-test; right und left: p=0,000), with 60% typical jaw-tracking

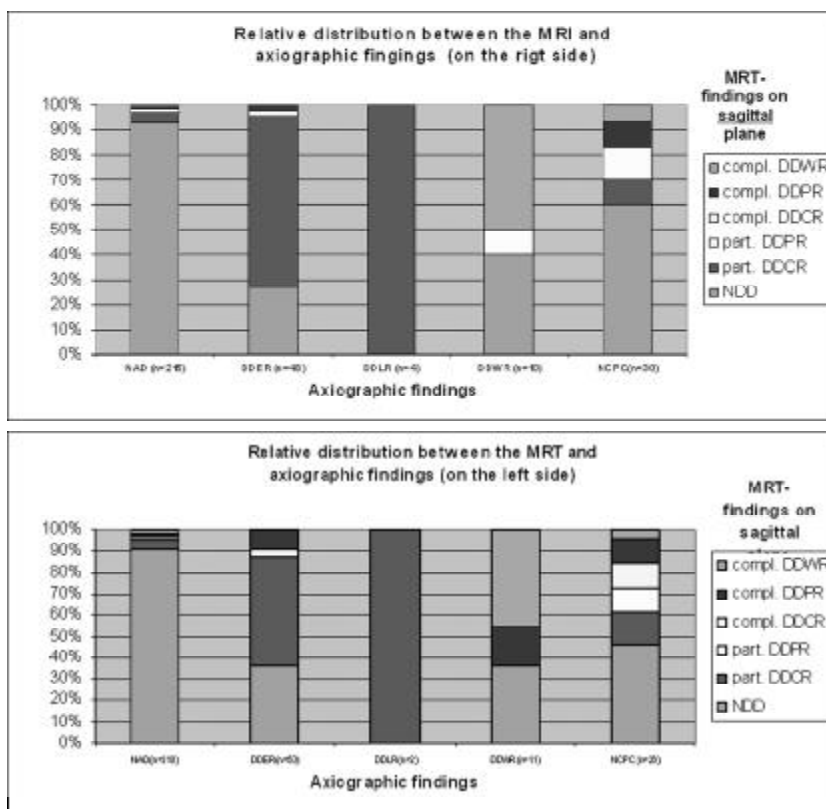


Figure 2. Relative distribution between the TMJ disk dislocation findings on MRT and axiography investigation of the right (superior graphic) and of the left (inferior graphic) joints.

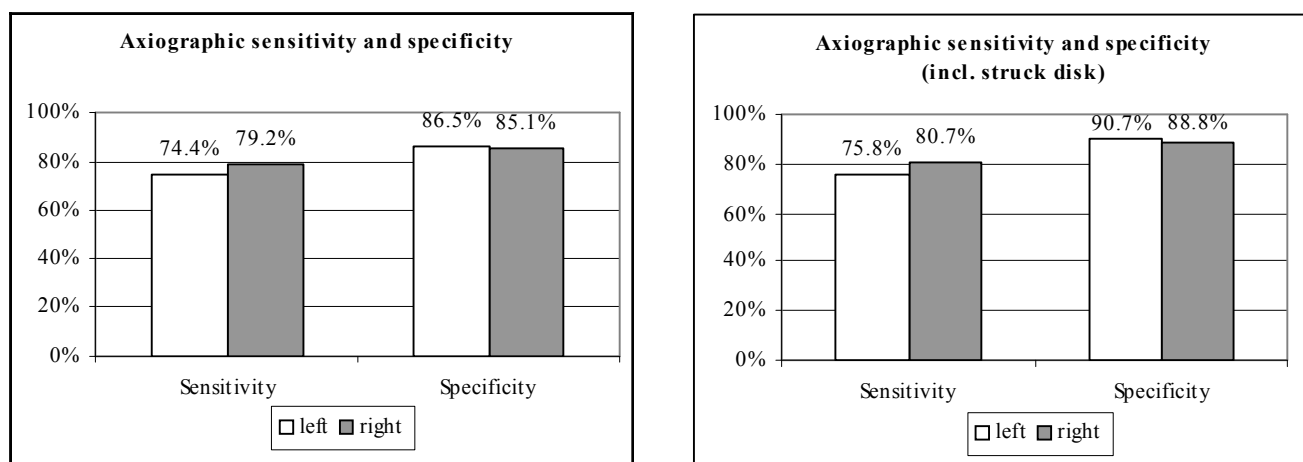


Figure 3: a) left: Diagrammed demonstration of the axiographic sensitivity and specificity;
b) right: Axiographic sensitivity and specificity with comprehension of the diagnosis "stuck disk".

characteristics. For that reason we assessed axiographic sensitivity and specificity once again including „stuck disk“ diagnosed on MRI (Figure 3: b) right). Sensitivity on the right joint raised to 80, 7% and specificity to 88, 8%. The positive predictive value for the right joint was 72, 8%. On the left side 24, 2% of the subjects were assessed wrongly as not diseased, so that resulted 75, 8% sensitivity. 9, 3% of the healthy subjects, who were assessed wrongly as diseased, therefore the specificity reached 90, 7% and the positive predictive value 77, 5%.

DISCUSSION AND CONCLUSION

Material and MRI standard

Former investigations on the usefulness of tracking devices for diagnoses of CMD had sample sizes of 5 to 39 patients and maximal 28 asymptomatic controls [11]. Due to small sample sizes there were usually no calculation of sensitivity and specificity, and no differentiation of specific TMJ disorders. In this investigation we did subgroup analysis from a populationally representative cross-sectional study - "Study of Health in Pomerania" (SHIP) on selected 307 subjects. For this reason we do not rebuild the patient and control groups. The sample size of 114 subjects with at least one sign of temporomandibular disorders and 193 controls allowed to distinguish healthy volunteers and six stages of ID.

Due to its non-invasive character and its excellent visualization of soft tissues, MRI is the method of choice for diagnosis of the correct disk position and bone changes of the TMJ. Its high sensitivity (67% -100%) was confirmed by autopsy studies [12].

Axiography

There is a big controversy in the literature about the use of a jaw-tracking device in the diagnosis of ADD. The meaning of these recordings is uncertain, as several authors [13-16] have reported, in view of sparse and unreplicated scientific evidence linking jaw tracking to the diagnosis of TMD. In contrast to this Rammelsberg et al. [11] estimates the jaw-tracking sensitivity of 86% and specificity of 90% in diagnosis of RDD. Sensitivity in diagnosing PDD reaches 75%. Piehslinger et al. [13] found, that in 70% of the ADD with and without reposition patient groups, axiography and MRT gave the same information. In other patient groups, axiography and MRI findings agreed in 45% of the cases. Piehslinger et al. [6] and Gsellmann et al. [17] showed in their investigations that although a large

percentage of morphologic alterations could be detected by MRT, axiography determined the dysfunctional dynamics more clearly. On the other hand it has to be noted that impairment of jaw movement is one of the signs of many TMJ disorders, and it is not surprising that quantification of jaw movement has been considered important. Reliable diagnostic evidence of axiography is complicated due to the fact, that PDD if exists for longer does not need to show limited tracks anymore. Short pathways of PDD are characteristic only if the displacement is recent. Should this blocking of the joint be of a longer duration, the masticatory system adapts itself to the new anatomic relationship. The amplitude of the pathways increases in size. They become long and regular and thus can no longer be distinguished from normal. There is no literature describing if such cases can be diagnosed using jaw-tracking device. Due to the fact, the disagreement about usefulness of a jaw-tracking device can be partially explained. There are till to date no generally accepted guidelines for the interpretation of jaw-tracking device. One possible reason saw Lückerrath [18] in the huge variety of recording systems, whose recordings could not be offhand compared with each other. On the other hand it has to be noted, that diagnostic criteria were proposed by authors that used clinical examination as standard. Sigaroudi et al. [19] found crossing and speed changes. Alsawaf et al. [20] found deflections in clicking joints. Zimmer et al. [21] measured a significantly bigger distance between in- and excursive movement. Parlett et al. [22] diagnosed RDD as an abrupt change in direction (with decelerations) leading to an inversion integral between in- and excursive path in at least one projection. PDD was combined with an absence of concavity (in sagittal projection) and a curvature length below 4-5 mm. They calculated an overall sensitivity of 54% (ADD with and without reduction). In relation to healthy volunteers 10% of false positive and 20% false negative diagnoses observed Rammelsberg et al. [11], if the split point of curvature length as indicator of PDD was fixed at 11 mm. However, the results of this study have clearly showed that in case of PDD the jaw tracking quantification was an unreliable remark. We observed in this study, that the concavity of the opening/closing tracking due to the pathological change was more significant than the tracking quantification. With the aid of this and with the simultaneously consideration of coincidently of protrusive-, mediotrusive- and opening/closing tracks, we reached a sensitivity of approximately 80% and specificity of approximately 90%. Within the limitations of this study we suggest, that jaw-tracking devices remains an accurate evaluation method for determination of TMJ dysfunction.

REFERENCES

1. Moritz M, Behr M, Held P, Dammer R, Niederdelmann H. Comparative study of results of electronic axiography with results of magnetic resonance imaging including MRI-assisted splint therapy. *Acta Stomatol Belg* 1995; 92(1): 35-8.
2. Dolwick MF, Riggs RR. Diagnosis and treatment of internal derangements of the temporomandibular joint. *Dent Clin North Am* 1983; 27(3): 561-72.
3. Emshoff R, Brandmaier I, Bertram S, Rudisch A. Comparing methods for diagnosing temporomandibular joint disc displacement without reduction. *J Am Dent Assoc* 2002; 133(4): 442-541.
4. Okeson JP. Management of temporomandibular disorders and occlusion. St Luis: Mosby; 2003.
5. Meyer G, dal Ri H. Dreidimensionale elektronische Messung der Bewegungen des Kondylus über die Scharnierachse des Unterkiefers. *Dtsch Zahnärztl Z* 1985; 40(8): 881-6. Ger.
6. Piehslinger E, Schimmerl S, Celar A, Crowley C, Imhof H. Comparison of magnetic resonance tomography with computerized axiography in diagnosis of temporomandibular joint disorders. *J Oral Maxillofac Surg* 1995; 24(1): 13-9.
7. Widmer CG, Lund JP, Feine JS. Evaluation of diagnostic tests for TMD. *J Calif Dent Assoc* 1990; 18(3): 53-60.
8. Mohl ND, McCall WS, Lund JP, Plesh O. Devices for the diagnosis and treatment of temporomandibular disorders: Part I. Introduction, scientific evidence, and jaw tracking. *J Prosthet Dent* 1990; 63(3): 198-201.
9. Theusner J, Plesh O, Curtis DA, Hutton JE. Axiographic tracings of temporomandibular joint movements. *J Prosthet Dent* 1993; 69(2): 209-15.
10. Kobs G, Bernhardt O, Meyer G. Magnetic resonance evaluation between the relationship of the temporomandibular joint disk and condylar head displacement. *Stom Baltic Dent Maxillofac J* 2003; (5): 93-6.
11. Rammelsberg P, Pospiech P, May HC, Gernet W. Evaluation of diagnostic criteria from computerized axiography to detect internal derangements of the TMJ. *J Craniomand Pract* 1996; 14(4): 286-95.
12. Schimmerl S, Kramer J, Stiglbauer R, Piehslinger E, Slavicek R, Imhof H. MRT des Kiefergelenks. *Fortschr Röntgenstr* 1993; 158(3): 192-96. Ger.
13. Greene CS. Can technology enhance TM disorder diagnosis? *J Calif Dent Assoc* 1990; 18(3): 25-33.
14. Widmer C.G., Lund J.P., Feine J.S.: Evaluation of diagnostic tests for TMD. *J Calif Dent Assoc* 1990; 18(3): 53-60.
15. Theusner J, Plesh O, Curtis DA, Hutton JE. Axiographic tracings of temporomandibular joint movements. *J Prosthet Dent* 1993; 69(2): 209-15.
16. Tsolka P, Preiskel HW. Kinesiographic and electromyographic assessment of the effects of occlusal adjustment therapy on craniomandibular disorders by a double-blind method. *J Prosthet Dent* 1993; 69(1): 85-92.
17. Gsellmann B, Kaida A, Paur T, Knaus A, Slavicek R. Vergleich der Befunde aus klinischer und instrumenteller Funktionsanalyse des Stomatognathen Systems. *Stomatologie* 1998; 95(8): 383-6. Ger.
18. Lückerath W. Zur Differentialdiagnostik elektronischer Aufzeichnungen der Gelenkbahnen funktionsgestörter Patienten. *Dtsch Zahnärztl Z* 1991; 46(11): 722-6. Ger.
19. Sigaroudi K, Knap FJ. Analysis of jaw movements in patients with temporomandibular joint click. *J Prosthet Dent* 1983; 50(2): 245-50.
20. Alsawaf M, Garlapo DA, Gale EN, Carter MJ. The relationship between condylar guidance and temporomandibular joint clicking. *J Prosthet Dent* 1989; 61(3): 349-54.
21. Zimmer B, Treichel A, Kubein-Meesenburg D. Achsographische Auffälligkeiten in Patientengruppen mit klinisch unterschiedlichen Funktionszuständen. *Dtsch Zahnärztl Z* 1990; 45(7 Spec No): 78-82. Ger.
22. Parlett K, Paesani D, Tallents RH, Hatala MA. Temporomandibular joint axiography and MRI findings: a comparative study. *J Prosthet Dent* 1993; 70(6): 521-31.

Received: 02 02 2004
Accepted for publishing: 20 03 2004