

Expression of gene proteins, interleukins and β -defensin in cleft-affected tissue

Iveta Jankovska¹, Mara Pilmane², Ilga Urtane¹

SUMMARY

Objectives. The aim of the study was to investigate cleft – affected tissues in children with cleft lip and palate in order to detect appearance of β -defensin, interleukins (IL) and gene proteins.

Material and methods. The study group included 10 patients with cleft lip and palate. During nose surgery tissue samples from bone and cartilage have been taken, and stained with immunohistochemistry for β -defensin 2, IL4, IL6, IL7, IL8, IL10 and MSX1, RYK, PAX9, IRF6 gene proteins.

Results. Results showed prominent expression of IL10 (mean value 47.28 ± 4.26 in visual field) followed by IL7 (35.62 ± 11.18) in cartilage of patients, but slightly less pronounced expression of IL8 (30.14 ± 8.74), IL6 (22.52 ± 10.88) and IL4 (14.81 ± 6.94). The expression of β -defensin 2 was prominent (34.52 ± 11.79) and similar to expression of IL7 in tissue samples of cartilage. MSX1, PAX9, RYK and IRF6 (17.67 ± 5.94 ; 16.14 ± 5.52 ; 16.57 ± 5.22 and 11.86 ± 4.21) in cartilage was less pronounced than interleukins and β -defensin 2. MSX1 (12.44 ± 3.34), PAX9 (6.89 ± 2.14), RYK (11.0 ± 5.92) and IRF6 (9.1 ± 4.76) gene proteins expression in bone showed mostly rare occurrence of positive structures.

Conclusions. Significant expression of IL7 and β -defensin 2 and IL10 in cartilage proves the prominent immune response in cleft affected hard tissue. Mostly indistinct MSX1, PAX9, RYK and IRF6 gene proteins expression in bone might be an indicator of not complete cellular differentiation, proliferation and migration events in cleft disordered hard tissue.

Key words: cleft lip and palate, immunohistochemistry.

INTRODUCTION

The most common craniofacial malformation worldwide in the newborn infants is the orofacial cleft, consisting of cleft lip with or without cleft palate and isolated cleft palate. These anomalies cause functional as well as esthetical disorders and decrease life quality for person. Cleft lip and palate affects approximately 1 of 300 to 1 of 2500 live births, with wide variability across geographic origin, racial and ethnic groups (1). In Latvia cleft lip and palate occur in 1 of 700-800 live births what is average occurrence in Europe population (2).

Literature data suggests that etiology of cleft lip with or without cleft palate and isolated cleft palate are caused by primary defects in the fusion of craniofacial processes that form the primary and secondary palate and separates the nasal and oral cavities. Fusion and migration of primary palate takes place at about the fifth or sixth week of embryonic life, whereas eleva-

tion and fusion of the secondary palate occurs at about six to eight weeks by a highly regulated process of mesenchymal proliferation and epithelial breakdown in three facial prominences: maxillary, the lateral nasal and medial nasal. Clefts of the palate can arise due to failure at any of several steps including palatal shelves elevation, migration, or fusion (3-5).

This complicated process in craniofacial region are strongly caused, controlled and regulated by multiple factors, such as growth factors, cytokines and neuropeptides. Some genes and gene proteins are also essential for facial development, and in last decade there have been dozens of studies about identification of genes or gene proteins that maybe responsible for skeletal anomalies and gene inactivation both in mouse and humans (6, 7). In general, it has been proposed that their differential expression controls patterning of the facial structures.

Family of homeobox genes is important in establishing of craniofacial, axial and appendicular skeletal pattern. Msx1 (Msh homeobox 1) is member of homeobox gene family and are widely expressed in many organs. It may have important role in limb formation, craniofacial development, odontogenesis,

¹Department of Orthodontics, Institute of Stomatology, Riga Stradins University, Riga, Latvia

²Department of Morphology, Institute of Anatomy and Anthropology, Riga Stradins University, Riga, Latvia

Address correspondence to Dr. Iveta Jankovska, Department of Orthodontics, Institute of Stomatology, Riga Stradins University, 20 Dzirciema Street, Riga, Latvia.
E-mail address: iveta.j@hotmail.com

and tumor growth inhibition. Mutations in the MSX1 gene may be associated in the pathogenesis of cleft lip and palate (8, 9). RYK gene belongs to a subclass of catalytically inactive, but otherwise distantly related, receptor protein tyrosine kinases (RTKs) and is essential for normal development and morphogenesis of craniofacial structures including the secondary palate (10). Recent studies also showed evidence of paired box gene 9 or PAX9 gene association in development of mammal dentition and nonsyndromic cleft lip with or without cleft palate (11), as well as IRF 6 or interferon regulatory factor 6 that could be related to development and formation of palate (12).

β -defensin 2 also known as skin-antimicrobial peptide 1 (SAP1) is a antibiotic peptide which is locally regulated by inflammation. β -defensin 2 is produced by epithelial cells and are expressed in all human epithelial tissues. In the oral cavity, the tissues that contain human β -defensins include: gingiva, tongue, salivary glands, and mucosa and has antimicrobial activity (13, 14).

Secreted proteins that bind to their specific receptors and play a role in the communication among leukocytes are named interleukins (IL). Although IL are a type of cytokines that have immunomodulatory functions-including cell proliferation, maturation, migration and adhesion, these cytokines also play an important role in subjects with non-syndromic cleft lip and palate in cross-talk between IL6 and transforming growth factor-beta 3 through regulation of extracellular matrix production by human fibroblasts. IL4 has been called the prototypic immunoregulatory cytokine and has an important role in regulating antibody production, hematopoiesis and inflammation, and the development of effector T-cell responses. IL6 has been mostly regarded as a pro-inflammatory cytokine but has many regenerative or anti-inflammatory activities. IL8 was identified as a neutrophil-specific chemotactic factor and later classified as a member of the CXC chemokine family. The major effector functions of IL8 are activation and recruitment of neutrophils to the site of infection or injury. Increased concentrations of IL8 were found in inflammatory sites in patients with diseases such as psoriasis and chronic obstructive pulmonary diseases. Interleukin 7 (IL7) plays a central, critical role in the homeostasis of the immune system and it is important in B and T cell development. Human interleukin 10 (IL10) is a potent anti-inflammatory cytokine that inhibits the synthesis of the major proinflammatory cytokines and chemokines (15, 16).

The aim of study was to investigate cleft-affected tissues in children with

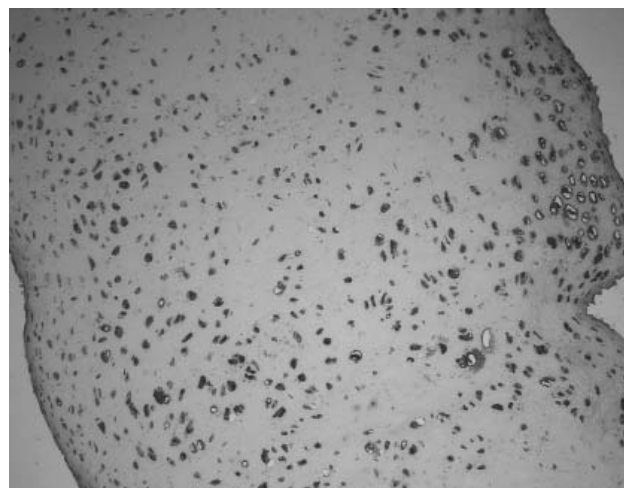


Fig. 1. Microphotograph of abundant IL10 containing cells in cartilage of cleft lip and palate patient, IMH, $\times 100$.

cleft lip and palate in order to detect appearance of β -defensin 2, IL4, IL6, IL7, IL8, IL10 and MSX1, RYK, PAX9, IRF6 gene proteins.

MATERIALS AND METHODS

Preliminary study group included totally 10 patients with cleft lip and palate in the age from 7 to 10 years with mean age 8.6 ± 1.03 years. Biopsy samples from cartilage and bone were taken during nose surgery at the Cleft Lip and Palate Centre of the Institute of Stomatology of Riga Stradins University. The study protocol was approved by the ethics committee of Riga Stradins University in May 2003.

Standard biotine and streptavidine immunohistochemical method (17) was used for the detection of gene proteins, β -defensin 2 and interleukins. The tissues samples were fixed in 2% formaldehyde and 0.2% picric acid in 0.1 M phosphate-buffer (pH 7.2). After that procedure they were washed in phosphate-buffered saline containing 10% saccharose for 12 hours, embedded in paraffin, and cut into 6-7 μm thick sec-

Table 1. Marking of relative frequency of immunohistochemically determined gene proteins, β -defensin and interleukins

Designations used	Explanations
0	No positive structures in the visual field
0/+	Rare occurrence of positive structures in the visual field
+	Few positive structures in the visual field
+ / ++	Few to moderate number of positive structures in the visual field
++	Moderate number of positive structures in the visual field
++ / +++	Moderate to numerous positive structures in the visual field
+++	Numerous positive structures in the visual field
+++ / ++++	Plenty of positive structures in the visual field

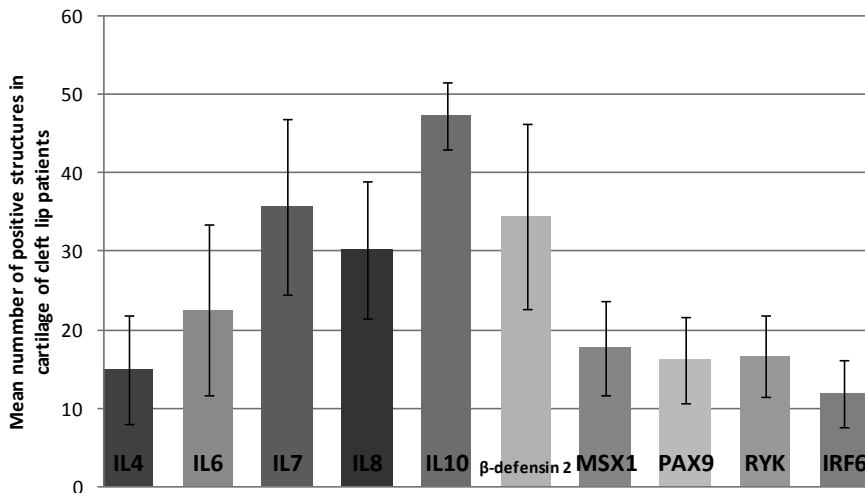


Fig. 2. Mean numbers and standard deviations of immunoreactive cells in cartilage of patients with cleft lip and palate.

tions. After deparaffinization slides were stained with biotin-streptavidin immunohistochemical method to detect presence of gene proteins MSX1 (orb18823, 1:100, Biorbyt Ltd., UK), IRF6 (ab167403, 1:100, Abcam, UK), PAX9 (orb120466, 1:100, Biorbyt Ltd., UK), RYK (orb38371, 1:100, Biorbyt Ltd., UK), β-defensin 2 (af27580, 1:100, RD Systems, UK), and interleukins IL4 (orb10908, 1:100, Biorbyt Ltd., UK), IL6 (sc130326, 1:50, Santa Cruz Biotechnology, USA), IL7 (orb48420, 1:100, Biorbyt Ltd., UK), IL8 (sc1269, 1:50, Santa Cruz Biotechnology Inc., USA), and IL10 (ab34843, 1:400, Abcam, UK).

To record the relative frequency of indices detected by the immunohistochemical method, a semi-quantitative counting method widely used in the literature was employed (18). The appearance frequency of factors was analyzed in three visual fields of each section (Table 1).

The data were analyzed using descriptive and analytical statistical methods. Counting of positive cells per 3 visual fields and calculation of mean value and standard deviation performed semi-quantitative analysis of the slides.

Table 2. Semiquantitative distribution of immunoreactive structures in the cartilage of patients with cleft lip and palate

Patient Nr.	IL4	IL6	IL7	IL8	IL10	MSX1	PAX9	RYK	IRF6	β-defensin2
1.	++/+++	++	++	++	+++/++++	++	++	+++	++	+++/++++
2.	+++/++++	+++/++++	+++/++++	+++	+++/++++	++	0/+	++	+	+++
3.	++	+++	+++	++/+++	+++	+/++	+	++	++	+++/++++
4.	+/++	+++	+++/++++	++	+++/++++	+	+	++	0/+	+++/++++
5.	+++	+++/++++	+++/++++	+++/++++	+++	+++	++	+++	++	+++/++++
6.	+/++	+++/++++	+++/++++	+++/++++	+++/++++	+++	+++	+++	++/+++	+++/++++
7.	+++	+++/++++	+++	+++/++++	+++/++++	+++	+++	++/+++	++	+++/++++

RESULTS

Analysis of the appearance of the studied gene proteins, interleukins and β-defensin in the bone and cartilage in cleft lip and palate patients revealed that the presence of these biological markers is rather variable (Tables 2, 3).

From all biological markers used in this study the most prominent was the expression of IL10 (mean value 47.28±4.26) and IL7 (mean value 35.62±11.18) in cartilage of patients with cleft lip and palate (Figures 1, 2), but slightly less pronounced expression of IL8 (mean value 30.14±8.74),

IL6 (mean value 22.52±10.88) and IL4 (mean value 14.81±6.94). In few cases tissue samples revealed plenty of positive structures in zone of proliferating cartilage with almost lack or few positive structures in other parts of sample (Fig. 3). Mainly expression of interleukins was evenly distributed, but in some cases appearance of positive structures was uneven, especially in expression of IL4 (Fig. 4). We observed significant expression of β-defensin 2 (mean value 34.52±11.79) in cartilage with numerous and/or abundance of positive structures in the visual field also (Fig. 5). Appearance of MSX1 (mean value 17.67±5.94), PAX9 (mean value 16.14±5.52), RYK (mean value 16.57±5.22) and IRF6 (mean value 11.86±4.21) was less pronounced than interleukins and β-defensin 2 and varied from occasional to numerous positive structures in the visual field in some patients but majority of samples revealed moderate number of positive structures in visual field (Figures 6, 7).

Tissue samples obtained from 3 cleft lip and palate patients were stained to detect appearance of MSX1 (mean value 12.44±3.34), PAX9 (mean value 6.89±2.14), RYK (mean value 11±5.92) and IRF6 (mean value 9.11±4.76) gene proteins expression in bone (Fig. 8) and showed

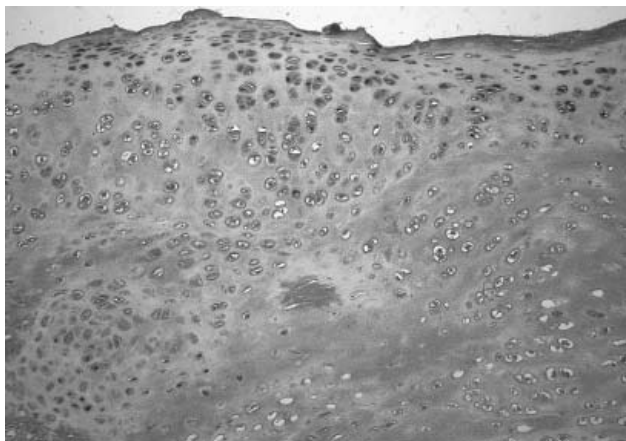


Fig. 3. Microphotograph of IL7 positive cells, especially in proliferation zone of cartilage of cleft lip and palate patient, IMH, ×200

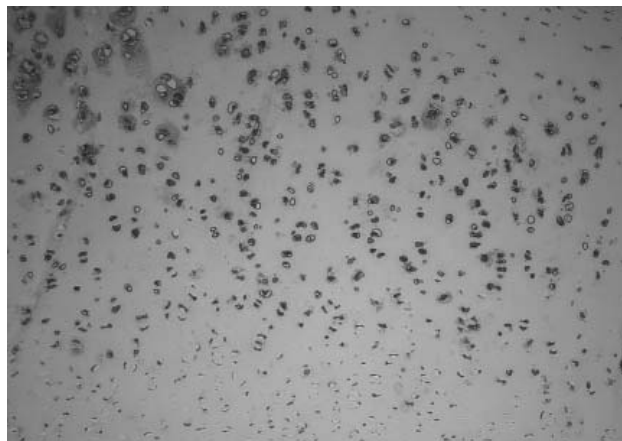


Fig. 4. Microphotograph of uneven appearance of IL4 positive structures in cartilage of cleft lip and palate patient, IMH, ×100

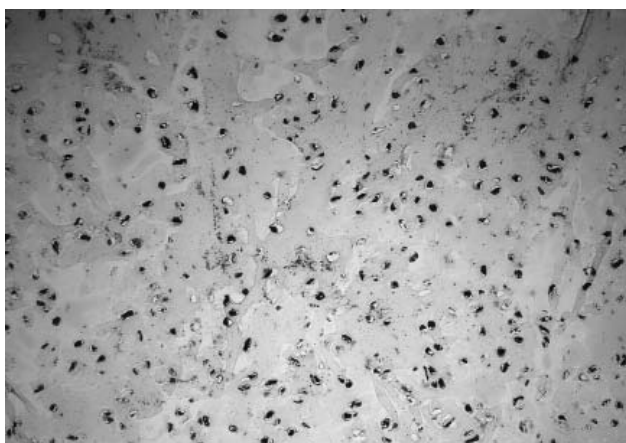


Fig. 5. Microphotograph of abundant β -defensin 2 immunoreactive cells in cartilage of cleft lip and palate patient, IMH, ×200

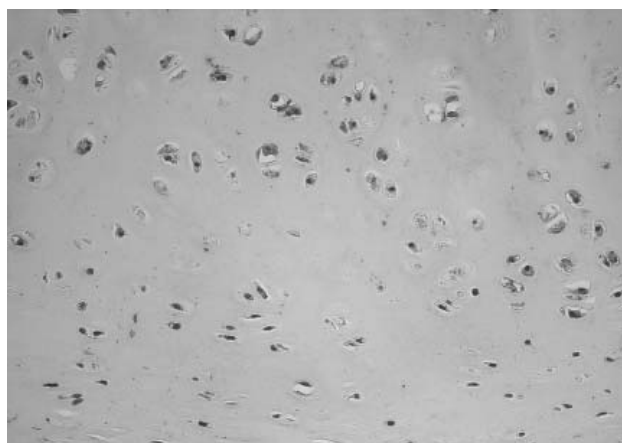


Fig. 6. Microphotograph of moderate MSX1 immunoreactive cells in cartilage of cleft lip and palate patient, IMH, ×200

mostly rare occurrence of positive structures in the visual field in exception of RYK gene protein that showed from few to moderate positive structures in visual field.

Two patients showed rather similar MSX1, PAX9, RYK and IRF6 gene protein expression that varied from no positive structures to moderate positive structures in visual field but one patient showed more pronounced gene protein expression. Interestingly that MSX1 and PAX9 expression in mature bone and periosteum differs significantly in all tissue samples.

In bone we saw occasional occurrence of positive structures in visual field but in periosteum mainly moderate to numerous positive structures in visual field. That was not the case in expression of RYK and IRF6. Appearance of positive structures in bone and

periosteum was distributed evenly. There was no difference between patients and all of them showed similar expression of these gene proteins.

DISCUSSION

In our study appearance of MSX1 and PAX9 was less pronounced than interleukins and β -defensin 2 in cartilage, as well as in bone and majority of samples revealed moderate number of positive structures in visual field.

Table 3. Semiquantitative distribution of immunoreactive structures in the bone of patients with cleft lip and palate

Patient Nr.	MSX1		PAX9		RYK		IRF6	
	Bone	Periosteum	Bone	Periosteum	Bone	Periosteum	Bone	Periosteum
8.	0/+	+++	+	++/+++	+++	+++	+++	+++
9.	+	+++	0/+	0/+	++	++	0	0/+
10.	0/+	++	0/+	+	+/++	+/++	0/+	0/+

0 – no positive structures in the visual field, 0/+ – rare occurrence of positive structures in the visual field, + – few positive structures in the visual field, +/++ – few to moderate number of positive structures in the visual field, ++ – moderate number of positive structures in the visual field, ++/+++ – moderate to numerous positive structures in the visual field, +++ – numerous positive structures in the visual field, +++/++++ – plenty of positive structures in the visual field.

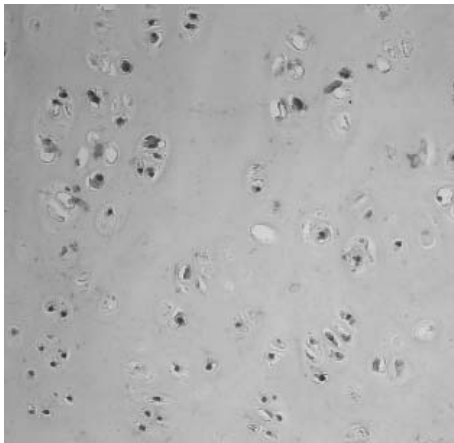


Fig. 7. Microphotograph of moderate PAX9 immunoreactive cells in cartilage of cleft lip and palate patient, IMH, $\times 200$

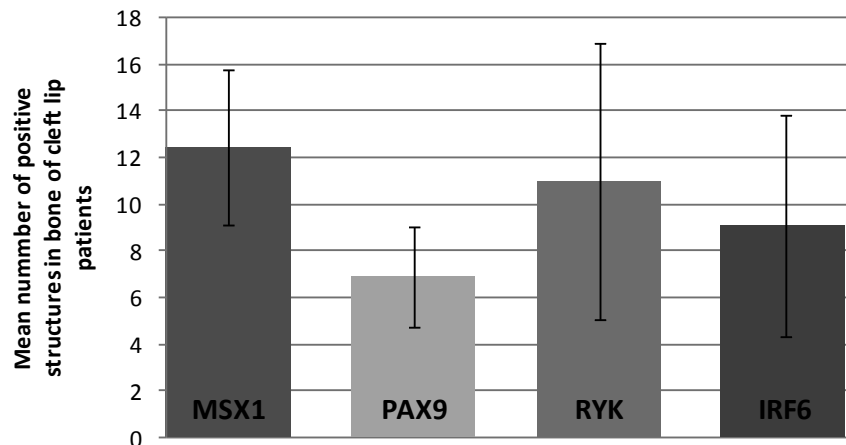


Fig. 8. Mean numbers and standard deviations of immunoreactive cells in bone of patients with cleft lip and palate

Clinically patients in our study had missing teeth (mostly upper lateral incisors) and microdontia. Dental anomalies in cleft lip and palate patients, such as missing teeth, supernumerary teeth, microdontia, taurodontism and transposition and/or ectopic teeth and hypoplastic teeth, are found frequently (19). In literature data we can see strong evidence that these dental anomalies are associated with some gene mutations, for example MSX1 and PAX9. Both genes are coexpressed in dental mesenchyme and appear critical for tooth morphogenesis, because in *Msx1* and *Pax9* homozygous null mutants, tooth organs arrest at the bud stage (20, 21). Nacatomi et al. (22) reported that a combined reduction of PAX9 and MSX1 gene dosage in humans may increase the risk for orofacial clefting and oligodontia and *Msx1* and *Pax9* interact synergistically throughout lower incisor development and affect multiple signaling pathways that influence incisor size and symmetry. Results from our study prove MSX1 and PAX9 involvement in tooth morphogenesis and development of cleft lip and palate. *Msx1* acts as a modeling factor for membranous bone also. It stimulates trabecular bone metabolism but limits cortical bone growth by promoting apoptosis, and concomitantly controls the collagen-based mineralization process (23). Indistinct MSX1 and PAX9 gene proteins expression in bone could be an indicator of not complete cellular differentiation, proliferation and migration events in cleft disordered hard tissue.

While no specific disease-causing gene mutations have been identified in non-syndromic clefting, a dozens of candidate genes have been isolated and RYK is one of them. Halford et al. (10) demonstrate that the mouse orphan receptor 'related to tyrosine kinases' (*Ryk*) is essential for normal development and morphogenesis of craniofacial structures including the secondary palate and mouse embryos deficient in RYK have craniofacial defects, for instance complete clefts of the secondary palate. IRF6 has not been widely studied in the connection to cleft lip and palate but there are some studies

indicating that IRF6 is involved in the development of cleft lip and palate also (24). Kondo et al. (25) preliminary findings in mice have revealed IRF6 expression in the medial edge epithelia of fusing secondary palatal shelves, tooth buds, hair follicles, and skin. In this study RYK and IRF6 expression showed mostly rare occurrence of positive structures in the visual field and was downregulated in cartilage and bone that could indicate involvement in the pathogenesis of cleft lip and palate.

β -defensin 2 was the second most evident biological marker stained for immunochemistry in our study and in almost all cases we observed plenty of positive structures in visual field. Human beta-defensins represent a major subclass of antimicrobial peptides and act as a first line of defense through their broad spectrum of potent antimicrobial activity. β -defensin 2 could be found in many inflammatory diseases, for example, periodontitis, peri-implantitis and osteoarthritis (23). Varoga et al. (26) in his study demonstrated that samples of osteomyelitis infected bone produce higher levels of endogenous antibiotics, such as human beta-defensin-2, when compared with samples of healthy bone. Our results proves the prominent immune response in cleft affected hard tissue This scientific information about β -defensin 2 in relation to our study may suggest that tissues from patients with cleft lip and palate are inflamed and could influence healing process after surgery.

IL4, IL10 are a well know anti-inflammatory and immunoregulatory cytokines, mainly released by, and acting on cells of the immune system such as monocytes, macrophages and T cells. IL10 is also produced by a few connective tissue cell types including chondrocytes and is involved in processes such as connective tissue extracellular matrix remodeling (27). IL7 stimulates production of proteases by IL7 receptor-expressing chondrocytes and enhances cartilage matrix degradation (28). DeBenedetti et al. (29) mentioned that mice transgenic for the inflammatory cytokine interleukin-6, expressing high circulat-

ing levels of IL6 since birth, show a marked decrease in growth rate leading to adult mice 50–70% the size of wild-type littermates. In our study significant appearance of IL7 and IL10 was seen in cartilage of patients with cleft lip and palate, but slightly less pronounced expression of IL4, IL6 and IL8, pointing that patient with cleft lip and palate presents disorders in immune response.

CONCLUSION

The most prominent was the expression of IL10

in tissue samples of cartilage with numerous and/or plenty of positive structures in the visual field and significant expression of IL7 and β -defensin 2, but slightly less pronounced expression of IL4, IL6 and IL8. Significant expression of IL10 and β -defensin 2 and IL7 in cartilage proves the prominent immune response in cleft affected hard tissue. Mostly indistinct MSX1, PAX9, RYK and IRF6 gene proteins expression in bone might be an indicator of not complete cellular differentiation, proliferation and migration events in cleft disordered hard tissue.

REFERENCES

- Watkins S, Meyer R, Strauss R, Aylsworth A. Classification, epidemiology, and genetics of orofacial clefts. *Clin Plast Surg* 2014; 41:149-163.
- Akota I, Barkane B, Grasmann N. The incidence of cleft lip and/or palate (CLP) in Latvia during years 1960 to 1997. *J Craniomaxillofac Surg* 2000; 28:Suppl.1;3.
- Leslie E, Marazita M., Genetics of Cleft Lip and Cleft Palate. *Am J Med Genet C Semin Med Genet* 2013; 163: 246–258.
- Gritli-Linde A. Molecular control of secondary palate development. *Dev Biol* 2007; 301:309–326.
- Meng L., Bian Z., Torensma R., Van den Hoff J., Biological mechanism in palatogenesis and cleft palate. *J Dent Res* 2009; 88:22-33.
- Erlebecher A., Filvaroff EH., Gitelman SE. Toward a Molecular Understanding of Skeletal Development. *Cell* 1995; 80:371- 378.
- Morgan BA, Tabin CJ. The role of homeobox genes in limb development. *Curr Opin Genet Dev* 1993; 3:668 – 674.
- Van den Boogaard MJ, Dorland M, Beemer FA, van Amstel HK. MSX1 mutation is associated with orofacial clefting and tooth agenesis in humans. *Nat Genet* 2000; 24: 342–343.
- Cardoso ML, Bezerra JF, Oliveira GH, Soares CD, Oliveira SR, de Souza KS et al. MSX1 gene polymorphisms in non-syndromic cleft lip and/or palate. *Oral Dis* 2013; 19:507-512.
- Halford M, Armes J, Buchert M, Meskenaitė V, Grail D, Hibbs M et al. Ryk-deficient mice exhibit craniofacial defects associated with perturbed Eph receptor crosstalk. *Nature Genetics* 2000; 25:414-418.
- Lee JK, Park JW, Kim YH, Baek SH. Association between PAX9 single-nucleotide polymorphisms and nonsyndromic cleft lip with or without cleft palate. *J Craniofac Surg* 2012; 23:1262-1266.
- Blanton SH, Cortez A, Stal S, Mulliken JB, Finnell RH, Hecht JT. Variation in IRF6 contributes to nonsyndromic cleft lip and palate. *Am J Med Genet A* 2005; 137A:259-262.
- Greer A, Zenobia C, Darveau RP. Defensins and LL-37: A review of function in the gingival epithelium. *Periodontol* 2013; 63: 67–79.
- Mayank H, Veenu MH. Epithelial Antimicrobial Peptides: Guardian of the Oral Cavity. *Int J Pept* 2014: 370297.
- Baroni T, Carinci P, Bellucci C, Lilli C, Becchetti E, Carinci F et al. Cross-talk between interleukin-6 and transforming growth factor-beta3 regulates extracellular matrix production by human fibroblasts from subjects with non-syndromic cleft lip and palate. *J Periodontol* 2003; 74:1447-1453.
- Akdis M, Burgler S, Cramer R, Eiwegger T, Fujita H et al. Interleukins, from 1 to 37, and interferon-gamma: receptors, functions, and roles in diseases. *J Allergy Clin Immunol* 2011; 127: 701–721.
- Hsu S, Raine L, Fanger H. The use of antiavidin antibody and avidin-biotin peroxidase complex in immunoperoxidase technics. *Am J Clin Pathol* 1981; 75:816-821.
- Knabe C, Nicklin S, Yu Y, Walsh W, Radlinski R, Marks C. Growth factor expression following clinical mandibular distraction osteogenesis in humans and its comparison with existing animal studies. *J of Cranio-Maxillofacial Surgery* 2005; 33:361-369.
- Al Jamal GA, Hazza'a AM, Rawashdeh MA. Prevalence of dental anomalies in a population of cleft lip and palate patients. *Cleft Palate Craniofac J* 2010; 47:413-420.
- Satokata I, Maas R. Msx1 deficient mice exhibit cleft palate and abnormalities of craniofacial and tooth development. *Nat Genet* 1994; 6:348-356.
- Peters H, Neubüser A, Balling R. Pax genes and organogenesis: Pax9 meets tooth development. *Eur J Oral Sci* 1998 Jan; 106 Suppl 1:38-43.
- Nakatomi M, Wang XP, Key D, Lund JJ, Turbe-Doan A, Kist R et al. Genetic interactions between Pax9 and Msx1 regulate lip development and several stages of tooth morphogenesis. *Dev Biol* 2010; 340:438-449.
- Pereira AL, Holzhausen M, Franco GC, Cortelli SC, Cortelli JR. Human β -defensin 2 and protease activated receptor-2 expression in patients with chronic periodontitis. *Arch Oral Biol* 2012; 57:1609-1614.
- Ibarra-Arce A, Garcia-Alvarez M, Cortes-Gonzales D, Ortiz de Zarate-Alarcon G, Flores-Pena L, Sanchez-Camacho S et al. IRF6 polymorphisms in Mexican patients with non-syndromic cleft lip. *Meta Gene* 2015; 4:8-16.
- Kondo, S, Schutte B, Richardson R, Bjork B, Knight A, Watanabe Y et al. Mutations in IRF6 cause Van der Woude and popliteal pterygium syndromes. *Nat. Genet* 2002; 32:285-289.
- Varoga D, Tohidnezhad M, Paulsen F, Wruck CJ, Brandenburg L, Mentlein R et al. The role of human beta-defensin-2 in bone. *J Anat* 2008; 213:749-757.
- Schulze-Tanzil G, Zreiqat H, Sabat R, Kohl B, Halder A, Müller RD, John T. Interleukin-10 and articular cartilage: experimental therapeutical approaches in cartilage disorders. *Curr Gene Ther* 2009; 9:306-315.
- Van Roon JA, Lafeber FP. Role of interleukin-7 in degenerative and inflammatory joint diseases. *Arthritis Res Ther* 2008;10:107
- De Benedetti F, Meazza C, Martini A. Role of interleukin-6 in growth failure: an animal model. *Horm Res* 2002; 58 Suppl 1:24-27.

Received: 08 05 2016
Accepted for publishing: 27 12 2017